



## Get Clarity On Generics

Cost-Effective CT & MRI Contrast Agents



FRESENIUS  
KABI

WATCH VIDEO

# AJNR

## Clinically silent infarcts shown by MR after cerebral angiography.

A Mamourian and B P Drayer

*AJNR Am J Neuroradiol* 1990, 11 (5) 1084

<http://www.ajnr.org/content/11/5/1084.citation>

This information is current as  
of August 22, 2025.

of high attenuation. The prosthetic lens is also thinner, only about 1–2 mm thick. It is otherwise in the same anatomic position and orientation as a native lens.

These characteristic CT features of an intraocular lens prosthesis readily distinguish it from most diseases of the intraocular lens or a traumatically introduced foreign body within the anterior chamber. It is theoretically possible that a similar appearance may be seen with posttraumatic cataracts with associated spontaneous phacolysis and various types of phacectomy, as a residual capsular membrane may be present [4]; however, we have not yet encountered such examples.

John C. Chaloupka  
Mauricio Castillo  
Emory University Hospital  
Atlanta, GA 30322

## REFERENCES

- Castillo M, Hudgins P. Incidental discovery of dislocated lens by computed tomography. *Arch Ophthalmol* 1989;107:489
- Hogan MJ, Alvarado JA, Weddell JE. *Histology of the human eye: an atlas and textbook*. Philadelphia: Saunders, 1971:33
- Williams PL, Warwick R, eds. *Gray's anatomy*, 36th ed. Philadelphia: Saunders, 1980:1176–1177
- Way LW. *Current surgical diagnosis and treatment*, 6th ed. Los Altos, CA: Lange, 1983:825

## Clinically Silent Infarcts Shown by MR After Cerebral Angiography

We report what we believe to be five cases of clinically silent infarcts shown on MR performed after cerebral angiography. One patient in the group was a 40-year-old man with a scalp mass who had brief nausea after vertebral arteriography. MR on the day after arteriography showed four areas of hyperintensity in the cerebellum on T2-weighted images (Fig. 1A) although the results of his neurologic examination were normal.

Another patient was a 60-year-old man with subarachnoid hemorrhage. Cerebral arteriograms were normal, and MR images obtained 1 day later were also normal. A second arteriogram was acquired 12 days after the first, and MR images obtained 1 week after the second angiogram showed what was thought to be a subacute infarct of the right caudate nucleus (Fig. 1B), not evident on the earlier MR examination.

In a third case, postangiographic MR showed what was thought to be a small cerebellar infarct in a 17-year-old patient and, in a fourth case, showed a basal ganglia infarct not seen on MR images obtained before angiography. In the fifth case, MR showed a left thalamic infarct in a 28-year-old man after angiography with multiple injections of contrast material into the vertebral artery.

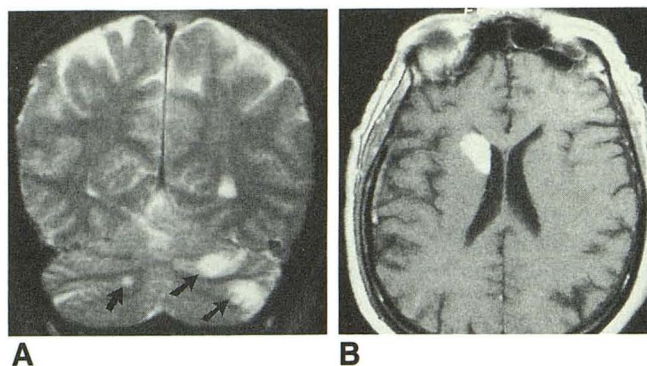


Fig. 1.—MR images obtained after cerebral angiography show clinically silent brain infarcts in two patients.

A, T2-weighted, coronal image, 200/80, of one patient shows multiple areas of increased signal in cerebellum (arrows).

B, Postcontrast, T1-weighted image, 500/30, of another patient shows intense signal arising from head of right caudate nucleus extending into internal capsule and putamen. This suggests breakdown of blood-brain barrier, consistent with subacute nature of this infarction.

Although the frequency of neurologic deficits associated with cerebral angiography is low [1–3], these five cases lead us to believe that the frequency of infarcts is higher than clinical studies would suggest. We wonder if this may be the tip of an iceberg of clinically silent, postangiographic infarcts that may be confusing if not recognized as such.

Alex Mamourian  
Burton P. Drayer  
Barrow Neurological Institute  
Phoenix, AZ 85013

## REFERENCES

- Dion JE, Gates PC, Fox AJ, Barnett HJ, Blom RJ. Clinical events following neuroangiography: a prospective study. *Stroke* 1987;18:997–1007
- Mani RL, Eisenberg RL, MacDonald EJ Jr, Pollock JA, Mani JR. Complications of catheter cerebral angiography: analysis of 5,000 procedures. I. Criteria and incidence. *AJR* 1978;131:861–865
- Kerber CW, Cromwell LD, Drayer BP, Bank WO. Cerebral ischemia. I. Current angiographic techniques, complications, and safety. *AJR* 1978;130:1097–1103

Editor's note.—Preangiographic MR studies were not available in all of these cases, and the causes of the infarcts are uncertain. However, this is an interesting hypothesis. The Journal would welcome additional letters or reports of controlled studies on this subject.

Letters are published at the discretion of the Editor and are subject to editing.

Letters to the Editor must not be more than two double-spaced, typewritten pages. One or two figures may be included. Abbreviations should not be used.

Material being submitted or published elsewhere should not be duplicated in letters, and authors of letters must disclose financial associations or other possible conflicts of interest.

Letters concerning a paper published in the *AJNR* will be sent to the authors of the paper for a reply to be published in the same issue. Opinions expressed in the Letters to the Editor do not necessarily reflect the opinions of the Editor.