



## Get Clarity On Generics

Cost-Effective CT & MRI Contrast Agents



FRESENIUS  
KABI

WATCH VIDEO

# AJNR

## Leptomeningeal metastasis from primary extracerebral neuroblastoma: CT demonstration.

D W Shaw, E Weinberger and D K Brewer

*AJNR Am J Neuroradiol* 1990, 11 (4) 804

<http://www.ajnr.org/content/11/4/804.citation>

This information is current as  
of August 23, 2025.

# Leptomeningeal Metastasis from Primary Extracerebral Neuroblastoma: CT Demonstration

Neuroblastoma is a tumor of early childhood that usually originates in the sympathetic ganglia or adrenal medulla [1, 2]. Except for the rare primary cerebral neuroblastoma, involvement of brain parenchyma and leptomeninges is unusual and tends to occur in cases of widely disseminated disease [3]. To our knowledge, we report the first CT demonstration of diffuse intracranial leptomeningeal metastases in a patient with neuroblastoma.

## Case Report

A 14-month-old boy had a large abdominal neuroblastoma. Skeletal scintigraphy showed bone lesions, and the results of a bone-marrow biopsy showed involvement of the bone marrow (stage IV disease). The findings of cytologic examination of CSF were normal. Cranial CT performed 14 weeks after the start of treatment showed normal brain and a small metastasis of left temporal bone. The abdominal mass enlarged despite therapy. Cranial CT at 33 weeks showed diffuse leptomeningeal enhancement and focal metastasis of the left sphenoid bone with extension into the middle fossa (Fig. 1). Examination of CSF obtained by lumbar puncture showed no malignant cells; and no bacteria, fungi, or yeast were found in samples of CSF cultured for up to 4 weeks. The patient was given 3500 cGy of whole-brain irradiation in 14 fractions. Two weeks later, head CT no longer showed meningeal enhancement. Bone scans, however, showed progressive disease, and aspirates of bone marrow showed severe panhypoplasia. The patient died 2 weeks later.

## Discussion

In adults, most leptomeningeal metastases are the result of leukemia, lymphoma, or carcinoma of the breast and lung [4]. In children, such metastases usually are associated with certain primary intracranial tumors, including medulloblastoma, ependymoma, pinealoma, and primary cerebral neuroblastoma [5]. Leptomeningeal involvement in primary extracerebral neuroblastoma is rare, but has been reported [3, 6, 7].

CT findings in leptomeningeal metastasis include sulcal-cisternal; ependymal-subependymal; and thickened, irregular tentorial enhancement [4]. In studies [4, 8, 9] in which the diagnosis was based on the results of cytologic examination of CSF or biopsy specimens or findings at autopsy, CT scans showed the metastases in 22–56% of cases. Because leptomeningeal metastases can impair resorption of CSF, communicating hydrocephalus may be the only CT finding [4].

The CT appearance of leptomeningeal metastasis may be mimicked by subarachnoid hemorrhage, meningeal infection (especially granulomatous), and subacute infarction with gyral enhancement [4, 9]. In our patient, the clinical course and the results of analysis of CSF make these conditions unlikely. The rapid resolution of sulcal-

cisternal enhancement after radiation therapy is consistent with the known radiation sensitivity of metastatic neuroblastoma [1].

Although neuroblastoma often grows into the spinal canal through intervertebral foramina [1] and often involves the skull and its dura [10], leptomeningeal metastasis is surprisingly uncommon. In a study [3] of all cases of childhood neuroblastoma treated in Denmark between 1943 and 1980, metastases to the meninges were seen in cases of widely disseminated tumors only. We found only two case reports [6, 7] that discuss diffuse leptomeningeal metastasis and that include cranial CT findings. Dresler et al. [6] describe a patient with congenital extraadrenal neuroblastoma with extension into multiple intervertebral foramina. Head CT showed dilated ventricles but no abnormal enhancement. At autopsy, tumor nodules were found in both the spinal and the cranial subarachnoid space. Gallet and Egelhoff [7] describe a 5-year-old with abdominal neuroblastoma and extradural involvement of the lumbar spinal canal. Cranial CT 1 year after start of treatment showed multiple enhancing lesions. The lesions appeared to be parenchymal but could have been meningeally based. In our patient, CT clearly showed leptomeningeal metastasis that resolved after radiation therapy.

Dennis W. W. Shaw

Edward Weinberger

David K. Brewer

University of Washington, School of Medicine

Children's Hospital and Medical Center

Seattle, WA 98105

## REFERENCES

1. Lanzkowsky P. *Pediatric hematology-oncology*. New York: McGraw-Hill, 1980:362–371
2. Bousvaros A, Kirks DR, Grossman H. Imaging of neuroblastoma: an overview. *Pediatr Radiol* 1986;16:89–106
3. Carlsen NLT, Schroeder H, Christensen IJ, et al. Signs, symptoms, metastatic spread and metabolic behavior of neuroblastomas treated in Denmark during the period 1943–1980. *Anticancer Res* 1987;7:465–473
4. Lee YY, Glass JP, Geoffroy A, Wallace S. Cranial computed tomographic abnormalities in leptomeningeal metastasis. *AJNR* 1984;5:559–563
5. Horten BC, Rubinstein LJ. Primary cerebral neuroblastoma: a clinicopathological study of 35 cases. *Brain* 1976;99:735–756
6. Dresler S, Harvey DG, Levisohn PM. Retroperitoneal neuroblastoma widely metastatic to the central nervous system. *Ann Neurol* 1979;5:196–198
7. Gallet BL, Egelhoff JC. Unusual CNS and orbital metastases of neuroblastoma. *Pediatr Radiol* 1989;19:287–289
8. Enzmann DR, Krikorian J, Yorke C, Hayward R. Computed tomography in leptomeningeal spread of tumor. *J Comput Assist Tomogr* 1978;2:448–455
9. Ascherl GF Jr, Hilal SK, Brisman R. Computed tomography of disseminated meningeal and ependymal malignant neoplasms. *Neurology (NY)* 1981;31:567–574
10. Zimmerman RA, Bilaniuk LT. CT of primary and secondary craniocerebral neuroblastoma. *AJR* 1980;135:1239–1242

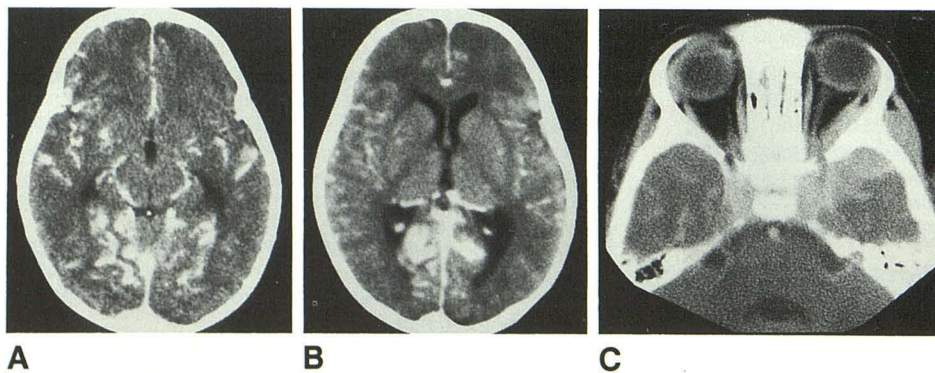


Fig. 1.—A–C, Contrast-enhanced cranial CT scans obtained at time of symptoms show sulcal and cisternal enhancement (A and B), especially about sylvian fissures and tentorium, and an enhancing soft-tissue mass (C) with epicenter about lateral aspect of left sphenoid bone extending into temporal fossa, floor of middle cranial fossa, and medial extraconal space.