



## Get Clarity On Generics

Cost-Effective CT & MRI Contrast Agents



FRESENIUS  
KABI

WATCH VIDEO

# AJNR

## **Gd-DOTA-enhanced MR imaging in two cases of Sturge-Weber syndrome.**

S Lipski, F Brunelle, J Aicardi, J F Hirsch and D Lallemand

*AJNR Am J Neuroradiol* 1990, 11 (4) 690-692

<http://www.ajnr.org/content/11/4/690.citation>

This information is current as  
of August 14, 2025.

## Gd-DOTA-Enhanced MR Imaging in Two Cases of Sturge-Weber Syndrome

S. Lipski,<sup>1</sup> F. Brunelle,<sup>1</sup> J. Aicardi,<sup>2</sup> J. F. Hirsch,<sup>3</sup> and D. Lallemand<sup>1</sup>

Sturge-Weber syndrome is characterized by the association of a trigeminal port-wine facial angioma with a pial venular angioma, usually ipsilateral to the facial nevus. However, a bilateral pial angioma may coexist with a unilateral facial nevus [1], and pial angioma may be present without any facial nevus [2]. The pial angioma is responsible for partial seizures, hemiplegia, and mental retardation. In typical cases, CT shows cortical calcifications and localized or diffuse hemiatrophy. Such findings were found, respectively, in 86% and 71% of our 14 cases in a companion study [3].

Direct demonstration of the pial angioma is difficult or impossible either by CT or angiography. Cortical enhancement after contrast injection is seen in the brain cortex and is thought to be due to blood-brain barrier breakdown resulting from prolonged episodes of seizures [3, 4] rather than to the angioma itself. Moreover, CT can be normal, especially in infants. Direct visualization of the pial angioma is of paramount importance in order to (1) ascertain the diagnosis when CT is normal or when the cutaneous angioma is lacking, (2) look for a bilateral pial angioma, and (3) identify precisely the extension of the angioma when surgical resection is contemplated.

We report two cases of proved Sturge-Weber syndrome in which the pial angioma was visualized by Gd-DOTA (Dotarem, Guerbet Laboratories, France).

### Case Reports

#### Case 1

A 10-month-old girl with a right facial port-wine nevus was admitted after one episode of left-sided convulsive status epilepticus that occurred at age 4 months. A left-sided spastic hemiplegia was first noted after that occurrence. Psychomotor development was mildly retarded. Brief, partial seizures with jerking of the left arm occurred several times a week. CT after the acute episode showed subcortical

calcifications in the right hemisphere as well as a small area of cortical calcification in the left frontal region (Figs. 1A and 1B).

MR imaging was performed on a 0.5-T scanner and T1-weighted spin-echo sequences were obtained before and after injection of Gd-DOTA. Before administration of Gd-DOTA, no abnormality was seen except for moderate bilateral widening of the pericerebral spaces. After injection, pial enhancement was visible, covering part of the right hemisphere, suggesting the presence of a diffuse angioma. A similar linear enhancement was evident over the left frontal region, indicating the presence of a contralateral angioma as well (Figs. 1C and 1D). Surgery was thought to be contraindicated because of bilateral angioma localization.

#### Case 2

A 2½-year-old boy with a left-sided facial nevus involving the upper eyelid and forehead was referred to us after repeated seizures featuring deviation of the eye toward the right side, loss of awareness, and loss of tone with consequent falls, despite carbamazepine therapy. His neuromental development appeared normal, as did the neurologic examination.

Plain CT showed left occipitotemporal gyral calcifications with ipsilateral hemispheric hypoplasia (Fig. 2A). Enhanced CT showed an enlarged left choroid plexus (Fig. 2B). There was no obvious cortical enhancement. MR imaging was performed on a 0.5-T scanner and T1-weighted spin-echo sequences, obtained without Gd-DOTA, showed only hypoplasia. Images obtained after injection of Gd-DOTA showed a thin stripe of enhancement covering the left occipital lobe and the posterior part of the left temporal lobe. Enlargement of the left choroid plexus was also seen (Figs. 2C and 2D).

At surgery, a pial angioma covered the external, inferior, and medial aspects of the occipital lobe, extending over the posterior part of the temporal lobe. The occipital lobe was removed en bloc and the corticectomy was extended anteriorly toward the medial aspect of the temporal lobe in an effort to remove the angioma entirely. Pathologic examination confirmed the diagnosis of pial angioma and of associated anoxic damage to the underlying cortex with multiple deep-seated calcifications. The postoperative course was uncomplicated; no seizures were observed in the immediate postoperative period.

Received May 31, 1989; revision requested July 18, 1989; revision received August 16, 1989; accepted August 29, 1989.

<sup>1</sup> Service de Radiologie, Hôpital des Enfants Malades, 149 rue de Sévres, 75743 Paris Cedex 15, France. Address reprint requests to F. Brunelle.

<sup>2</sup> Unité de Neurologie et Inserm, Hôpital des Enfants Malades, Paris, France.

<sup>3</sup> Service de Neurochirurgie, Hôpital des Enfants Malades, Paris, France.



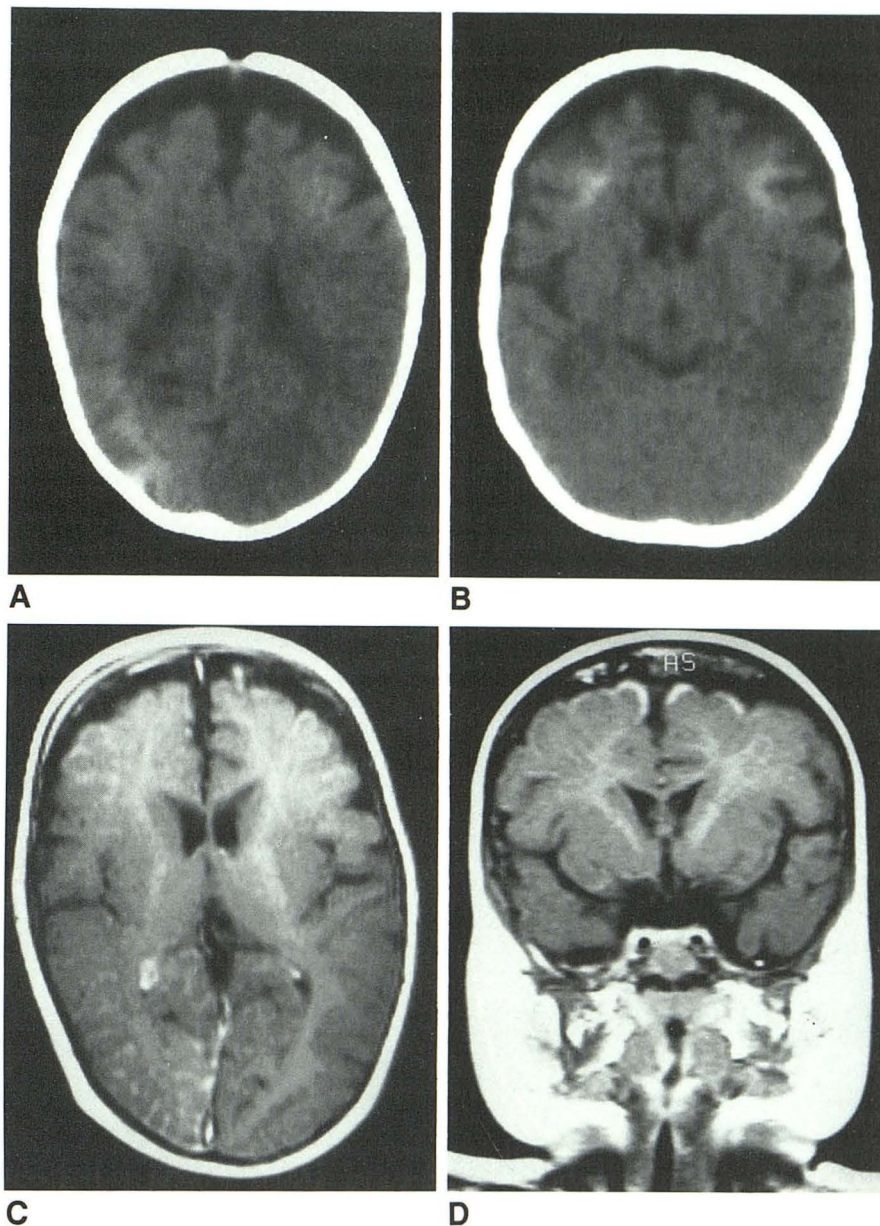
Fig. 1.—Case 1.

A, Plain CT. Diffuse right hemispheric calcifications are seen as well as bilateral moderate atrophy.

B, Plain CT. Left frontal calcifications are visible.

C, Axial enhanced T1-weighted MR image. Meningeal enhancement is well seen over much of right hemisphere but left frontal meningeal enhancement is barely seen.

D, Coronal enhanced MR image. Bilateral meningeal enhancement is conspicuous superiorly.



## Discussion

The diagnosis of Sturge-Weber syndrome can be made easily in most cases by CT, but it rests almost exclusively on indirect signs, such as cortical calcifications, enlarged choroid plexus, postictal cortical enhancement, or abnormal venous drainage [3]. Direct visualization of the angioma is seldom, if ever, observed, probably because of the thinness of the angiomatous layer, the presence of calcifications in the same area, and the immediate vicinity of the highly dense cranial vault. MR imaging, because cortical bone and calcifications give no signal, permits a fine analysis of the cortex and overlying meninges. In our two patients, enhancement of the cortical surface became apparent after injection of Gd-DOTA.

In the second patient, good topographic correlation was found between surgery and MR results. This suggests that the cortical enhancement actually represents the pial angioma itself. Such an enhancement is not unexpected because of the vascular nature of the meningeal anomaly and the low blood flow within its multiple channels.

If these preliminary findings are confirmed in further cases, Gd-DOTA or Gd-DTPA-enhanced MR imaging will be the procedure of choice for demonstrating the presence and extent of pial angioma in Sturge-Weber syndrome, as both substances have proved to be safe and well tolerated in children [5]. The detection of otherwise unrecognizable bilateral involvement will allow an easier and safer surgical therapeutic approach in selected patients.



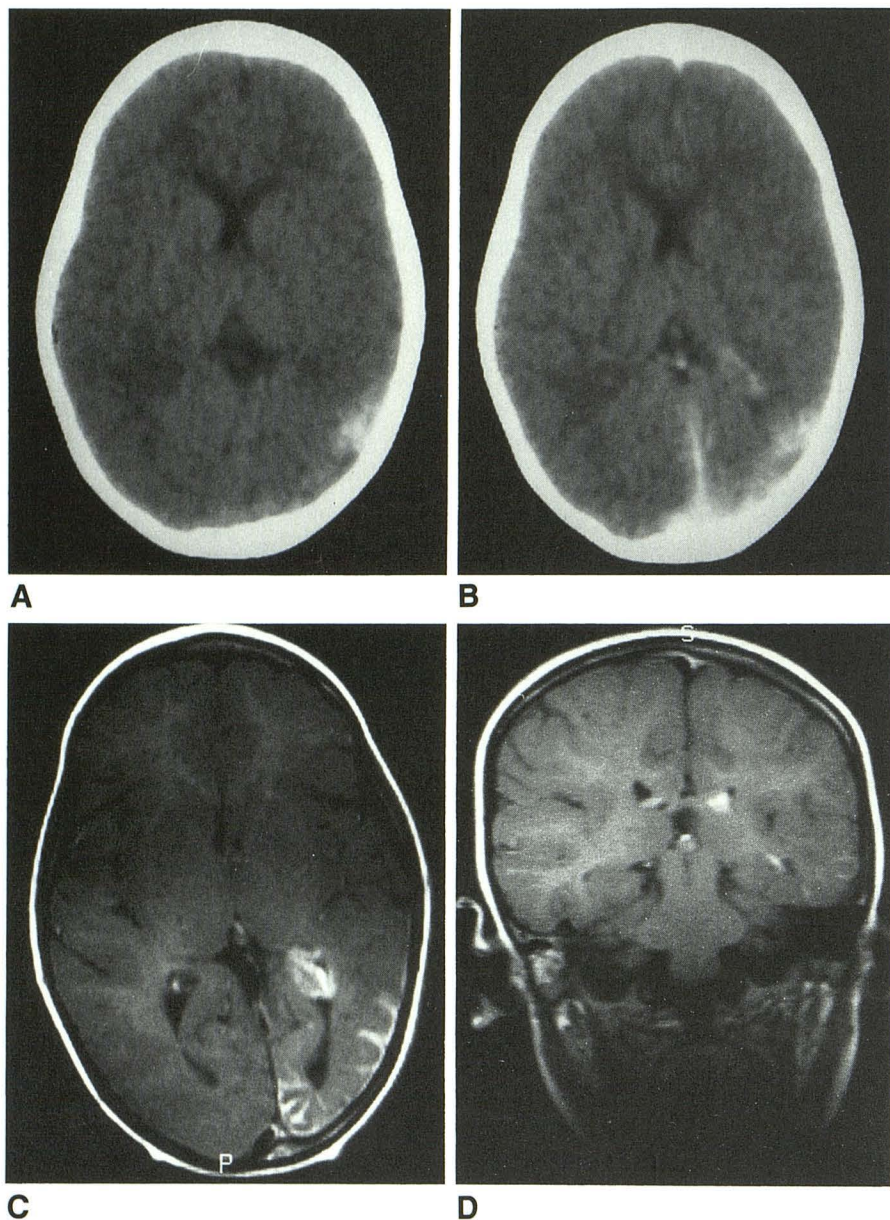


Fig. 2.—Case 2.

A, Plain axial CT. Left parietooccipital calcifications are visible.

B, CT after contrast infusion. Enlarged left choroid plexus is seen.

C, Axial enhanced MR image. Diffuse left occipital meningeal enhancement is visible.

D, Coronal enhanced MR image. Temporal meningeal enhancement and prominent choroid plexus are visible on the left.

#### REFERENCES

1. Boltshauser E, Wilson J, Hoare RD. Sturge-Weber syndrome with bilateral intracranial calcifications. *J Neurol Neurosurg Psychiatry* 1976;39:429-435
2. Gorman MJ, Snead OC. Sturge-Weber syndrome without portwine nevus. *Pediatrics* 1977;60:785-786
3. Terdjman P, Aicardi J, Brunelle F. Sturge Weber syndrome in children—CT and angiographic findings. Presented at the annual meeting of the European Society of Paediatric Radiology, Montreux, April 1988
4. Aicardi J, Chevrie JJ. Consequences of status epilepticus in infants and children. In: Delgado-Escueta AV, Wasterlain CG, Treiman DM, Porter RJ, eds. *Advances in neurology*, vol. 34. *Status epilepticus*. New York: Raven, 1983:115-125
5. Lipski S, Baraton J, Taviere V, Mamou Mani T, Brunelle F, Lallemand D. Gd-Dota enhanced MR in neuropaediatric patients. Presented at the annual meeting of the European Society of Paediatric Radiology, Dublin, May 1989