



**Providing Choice & Value**

Generic CT and MRI Contrast Agents



**FRESENIUS  
KABI**

**CONTACT REP**

**AJNR**

**CT myelography of a fragment of a lumbar disk  
sequestered posterior to the thecal sac.**

J D Lutz, R R Smith and H M Jones

*AJNR Am J Neuroradiol* 1990, 11 (3) 610-611

<http://www.ajnr.org/content/11/3/610.citation>

This information is current as  
of July 29, 2025.

## CT Myelography of a Fragment of a Lumbar Disk Sequestered Posterior to the Thecal Sac

The radiologic manifestations of lumbar disk herniation as seen on myelography, postmyelography CT, and, more recently, surface-coil MR have been well described [1–3]. CT and MR findings of far lateral, extraforaminal disk herniation also have been reported [4]. Migratory fragments typically settle anterior and/or lateral to the thecal sac [5]. We report a case in which the sequestered migratory fragment from a herniated lumbar disk was located primarily posterior (dorsal) to the thecal sac.

### Case Report

The patient was a 30-year-old construction worker and martial arts hobbyist with chronic low back pain. Acute exacerbation of the pain began 5 days before admission when he sneezed. He had immediate midline low back pain with radiation down the posterior thighs and paresthesias bilaterally in the lower extremities. Numbness in the buttocks and penis developed more gradually over the intervening 5 days, with impotence and constipation also. No episodes of urinary incontinence occurred; however, he did have increased difficulty voiding and had dribbling afterward. Neurologic examination showed 5/5 motor strength in both lower extremities, with the exception of plantar flexion, which was 3/5 bilaterally. Performance of the heel-to-shin test was poor bilaterally. Sensory examination revealed decreased sensation to pinpricks in the right S1 and bilateral S2 distribution. Rectal tone was poor.

The clinical findings suggested acute herniated nucleus pulposus with cauda equina syndrome, and emergency myelography was performed. After contrast medium was instilled at the L2–L3 level, a complete block was encountered at L4–L5 (Fig. 1). Postmyelography CT showed a disk herniation at L4–L5 with a large sequestered fragment in the lateral recess on the right at L4. Most of the fragment continued posterior to the thecal sac at that point, with its cephalic extent at the mid-L4 vertebral body. L4 and L5 laminectomies were performed, and a large sequestered fragment primarily dorsal and right lateral to the thecal sac was removed. The aggregate fragments were 5 × 4 × 1 cm. The patient's postoperative course was smooth and uncomplicated, with nearly immediate relief of pain and complete resolution of neurologic deficits.

### Discussion

The herniated parts of a nucleus pulposus can remain in a subligamentous location. They may retain continuity with the parent disk or may become free fragments. The free fragments migrate superiorly or inferiorly with relatively equal frequencies [5]. Lateral subligamentous migration is influenced by a sagittal midline septum that connects the posterior longitudinal ligament to the dorsum of the vertebrae. This septum directs the fragment laterally to the midline and into the lateral recess [6]. Herniated fragments that rupture through the posterior longitudinal ligament have been termed sequestered fragments [3]. These fragments are free to migrate in any direction.

A case of a degenerated cervical disk with a sequestered fragment posterior to the thecal sac has been reported [7]. Plain film tomography showed calcification of the fragment. Apparently, no cases of fragments of the lumbar disk sequestered posterior to the thecal sac have been published.

The patient in our case was stoic, and his injury occurred in a relatively atypical manner (sneezing). When he was first examined, he was sent home on symptomatic therapy and bed rest, but he continued to ambulate for 5 days. We hypothesize that his stoicism and continued activity were essential to the later findings. His disk herniation may have been lateral at first, but over the intervening 5 days, the fragment continued to extrude and eventually became sequestered. The large size of the fragment eventually exceeded the limits of the lateral recess and/or the anterior epidural space, and the fragment subsequently settled posterior to the thecal sac because of spatial and size constraints.

The differential diagnosis of lumbar disk extrusion and sequestration has been well described. It has been suggested that abnormal soft tissue within the spinal canal that is other than posterior or posterolateral to the disk margin makes an alternative cause more likely [5]. The differential diagnosis includes epidural neoplasm, such as metastasis, chordoma, lipoma, or lymphoma. Other causes are epidural abscess, hematoma, postoperative fibrosis, synovial cyst of the facet joint, and osteophyte of the facet. In most cases, the differential diagnosis can be narrowed on the basis of the attenuation of the mass on CT (e.g., lipoma, cyst, or osteophyte) or the presence of central low density (e.g., abscess). MR may be helpful in differentiating most of these processes.

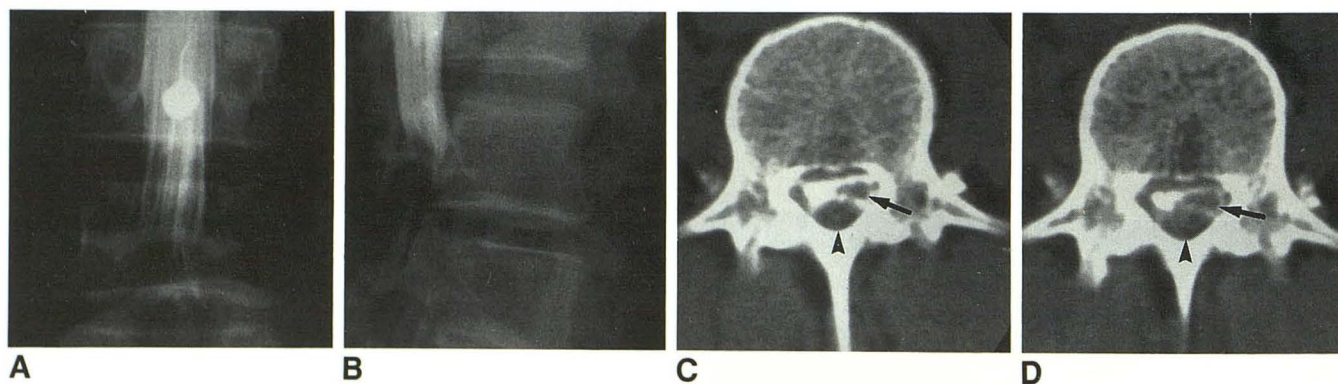


Fig. 1.—Sequestered fragment of a herniated lumbar disk.

A and B, Posteroanterior (A) and lateral (B) plain myelograms of lumbar spine after instillation of contrast medium show a posterior extradural defect at level of L4 and complete myelographic block at L4–L5.

C and D, Sequential contiguous 5-mm axial CT scans at level of L4 show a soft-tissue fragment with density of a disk posterior (dorsal) to thecal sac (arrowheads). Nerve roots are displaced laterally to left (arrows). Sequestered fragment continued inferiorly to level of complete myelographic block at L4–L5 disk.

In conclusion, lumbar disk disease is a common entity that occasionally may present in an atypical manner. This case of a sequestered fragment of a lumbar disk posterior to the thecal sac broadens the differential considerations of soft-tissue density seen in this location on CT. In a young, otherwise healthy person who has a high pain threshold and who delays seeking treatment, sequestered fragments may migrate to unusual locations.

James D. Lutz  
Richard R. Smith  
Henry M. Jones

*Indiana University, School of Medicine  
Indianapolis, IN 46202-5253*

#### REFERENCES

1. Williams AL, Haughton VM, Syvertsen A. Computed tomography in the diagnosis of herniated nucleus pulposus. *Radiology* **1980**;135:95-99
2. Edelman RR, Shoukimas GM, Stark DD, et al. High-resolution surface-coil imaging of the lumbar spine with CT correlation. *AJNR* **1985**;6:237-245
3. Masaryk TJ, Ross JS, Modic MT, Boumpfrey F, Bohlman H, Wilber G. High-resolution MR imaging of sequestered lumbar intervertebral disks. *AJNR* **1988**;9:351-358
4. Osborn AG, Hood RS, Sherry RG, Smoker WRK, Harnsberger HR. CT/MR spectrum of far lateral and anterior lumbosacral disk herniations. *AJNR* **1988**;9:775-778
5. Dillon WP, Kaseff LG, Knackstedt VE, Osborn AG. Computed tomography and differential diagnosis of the extruded lumbar disc. *J Comput Assist Tomogr* **1983**;7(6):969-975
6. Schellinger DC, Patronas NJ, Muraki AS, Abdulla DC, Manz HT. Influence of anterior epidural space anatomy on modus of disk fragment migration. Presented at the 74th annual meeting of the Radiological Society of North America, Chicago, November **1988**
7. Manabe S, Tateishi A. Epidural migration of extruded cervical disc and its surgical treatment. *Spine* **1986**;11(9):873-878