



**Providing Choice & Value**  
Generic CT and MRI Contrast Agents

**FRESENIUS  
KABI**

**CONTACT REP**

**AJNR**

**Unilateral double carotid cavernous fistula  
treated with detachable balloons.**

G Wilms

*AJNR Am J Neuroradiol* 1990, 11 (3) 517

<http://www.ajnr.org/content/11/3/517.citation>

This information is current as  
of July 18, 2025.

## Unilateral Double Carotid Cavernous Fistula Treated with Detachable Balloons

Direct fistulas between the internal carotid artery and the cavernous sinus are mostly posttraumatic and are due to laceration of the carotid siphon or rupture of its intracavernous branches [1]. The fistula is usually unilateral but can be bilateral [1, 2]. In general, only one communication occurs between the carotid siphon and the cavernous sinus, as was shown in a large number of cases when the defect in the vessel wall was closed via balloon embolization [3–5]. We report a case of posttraumatic carotid cavernous fistula in which two defects were present in the carotid siphon.

### Case Report

While extracting a nail from a wall, a 43-year-old man hit his left orbit with a pair of tongs; he was unconscious for 30 sec. Afterward, his left eye was painful, but no penetrating injury had occurred. The next morning, he noticed swelling of the upper eyelid and sensation of pressure in the left hemicranium. During the following days, chemosis and exophthalmos without ophthalmoplegia developed, and he began hearing a noise. He had conjunctival engorgement, proptosis, and a systolic bruit over the left orbit. His vision was normal. Radiographs of the skull did not show any fracture of the orbital bones. Selective internal carotid angiography showed a double fistula of the C4 segment of the carotid siphon (Figs. 1A and 1B). The ventral fistula drained mostly into the superior ophthalmic vein. The dorsal fistula was in direct communication with the cavernous sinus and drained into the inferior petrosal sinus. No external carotid artery feeders to the fistulas were present. Embolization with detachable balloons was performed via the femoral route. The ventral fistula was occluded by one 1-mm balloon (Fig. 1C), but three balloons (two 2 mm and one 1 mm) were necessary to occlude the dorsal fistula (Fig. 1D). The balloons were filled with diluted contrast medium. After the procedure, the exophthalmos, the chemosis, and the noise disappeared within 10 days. A total sixth nerve palsy and a partial third nerve palsy developed, with discrete ptosis and anisocoria. Clinical examination 4 months after embolization confirmed total closure of the carotid cavernous fistulas. The sixth nerve palsy persisted. Follow-up radiographs of the skull showed that the two balloons were still fully inflated.

### Discussion

The cavernous part of the internal carotid artery, fixed to the surrounding dura at the base of the skull, is exposed to shearing stresses [1]. In blunt orbital trauma, such stresses are probably the cause of laceration of the carotid siphon. This most commonly leads to one defect in the carotid siphon, but in our case, a double carotid cavernous fistula occurred. The dorsal fistula communicated widely with the cavernous sinus, but the ventral fistula was small, so we thought they were a ruptured intracavernous branch, such as the inferolateral trunk. Selective injection of the internal maxillary artery, however, did not fill the two fistulas.

Balloon embolization is an established method of treating carotid cavernous fistulas [1–5]. In our patient, it was particularly useful because it selectively occluded both fistulas and preserved flow in the internal carotid artery. Moreover, the final proof of a double arteriovenous communication was the demonstration that the ventral fistula was occluded by a detachable balloon, indicating the presence of a second defect in the carotid siphon.

G. Wilms

University Hospitals K. U. Leuven  
Leuven, Belgium

### ACKNOWLEDGMENT

I thank P. Lasjaunias (Le Kremlin, Bicêtre, Paris) for his assistance in the preparation of the manuscript and for his educational efforts in the art of embolization.

### REFERENCES

1. Lasjaunias P, Berenstein A. *Surgical neuroangiography. Part 2: Endovascular treatment of craniofacial lesions*. New York: Springer-Verlag, 1987: 175–211
2. Kendall B. Results of treatment of arteriovenous fistulae with the Debrun technique. *AJNR* 1983;4:405–408
3. Debrun GM. Treatment of traumatic carotid-cavernous fistula using detachable balloon catheters. *AJNR* 1983;4:355
4. Norman D, Newton TH, Edwards MS, DeCaprio V. Carotid-cavernous fistula: closure with detachable silicone balloons. *Radiology* 1983;149: 149–157
5. Scialfa G, Valsecchi F, Scotti G. Treatment of vascular lesions with balloon catheters. *AJNR* 1983;4:395–398

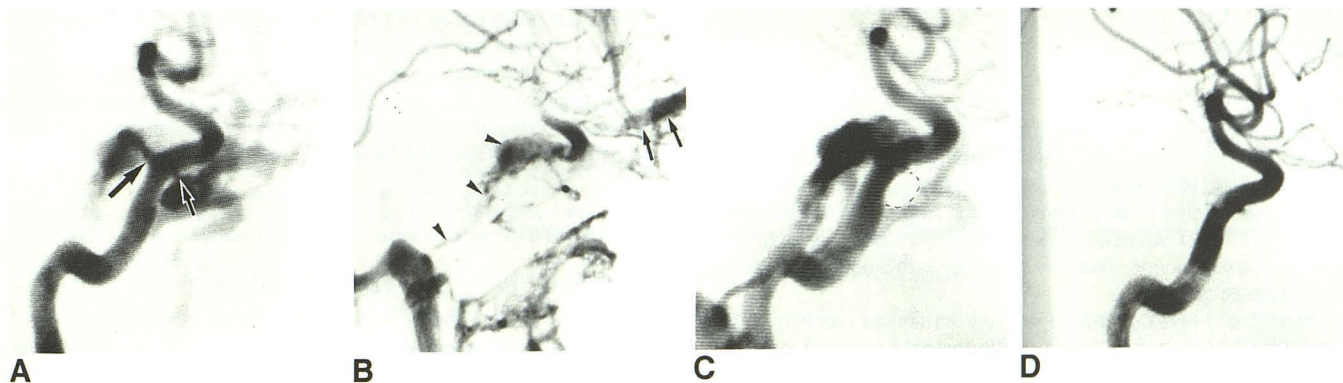


Fig. 1.—Selective left internal carotid angiograms of unilateral double carotid-cavernous fistula.  
A, Arterial phase shows ventral and dorsal fistulas (arrows) of C4 segment of left internal carotid artery.  
B, Venous phase shows ventral fistula draining into superior ophthalmic vein (arrows) and dorsal fistula into cavernous and inferior petrosal sinuses (arrowheads).  
C, Dotted line indicates balloon in ventral fistula after occlusion of this fistula. Dorsal fistula is still open.  
D, Lateral view shows balloon in place in dorsal fistula before detachment.