



**Providing Choice & Value**

Generic CT and MRI Contrast Agents



**FRESENIUS  
KABI**

**CONTACT REP**

**AJNR**

**MR imaging of the brain in five members of a family with Pelizaeus-Merzbacher disease.**

A M Silverstein, D K Hirsh, J D Trobe and S S Gebarski

*AJNR Am J Neuroradiol* 1990, 11 (3) 495-499

<http://www.ajnr.org/content/11/3/495>

This information is current as  
of July 31, 2025.

# MR Imaging of the Brain in Five Members of a Family with Pelizaeus-Merzbacher Disease

Andrew M. Silverstein<sup>1</sup>  
David K. Hirsh<sup>2</sup>  
Jonathan D. Trobe<sup>2</sup>  
Stephen S. Gebarski<sup>1</sup>

MR imaging was performed in five members of a family afflicted with Pelizaeus-Merzbacher disease. The individuals imaged included a male proband, his mother, and three maternal uncles. Clinically affected members showed generalized white matter signal aberration consistent with dys- and demyelination, basal ganglia, and thalamic signal aberration suggestive of pathologic iron storage and diffuse brain atrophy. These findings are similar to those seen in other leukodystrophies. The proband's mother was normal by neurologic examination but showed a suspicious but not definitely abnormal similar pattern of basal ganglionic and white matter signal aberration.

In our limited patient sample, MR appears to be able to: (1) demonstrate a pattern of imaging abnormalities characteristic of Pelizaeus-Merzbacher disease (we do not know if this pattern is specific); (2) potentially detect the obligate carrier state; and (3) detect the facultative carrier state.

*AJNR* 11:495-499, May/June 1990

Pelizaeus-Merzbacher disease (PMD) is a rare leukodystrophy predominantly transmitted as an X-linked recessive gene. To our knowledge, there has been no previous work describing and comparing MR imaging findings of members of a family afflicted with the disease. We present MR findings of our proband, a 23-month-old boy, as well as his mother and three maternal uncles.

## Materials and Methods

Brain MR was obtained on a 1.5-T Signa unit (General Electric, Milwaukee, WI) using spin-echo technique with a standard head coil. Axial and sagittal T1-weighted images, 600/20/2 (TR/TE/excitations), were obtained as well as axial and coronal T2-weighted images (3000/30,90/2). Flow compensation was employed on the long TR images to improve quality. The matrix used was 256 × 128, slice thickness was 5 mm, and the field of view was 20 cm.

## Case Reports

### Case 1

Following an uncomplicated pregnancy and delivery, this boy was observed by his parents to have unusual eye and head movements. At that time, an ophthalmologist diagnosed this as congenital nystagmus and made no further evaluation. Cognitive and motor developmental milestones were delayed at 6 months of age. Several months later, he was noted to be slow to achieve new milestones but had lost none. At age 15 months, EEG was normal. Brain CT was normal at age 19 months. He had episodes of staring accompanied by unresponsiveness and flaccidity. At presentation to the Department of Ophthalmology, he was 23 months old and was alert and socially interactive, although not appropriately for his age. He had a 10-15 word vocabulary. Physical examination demonstrated head titubation as well as upper limb ataxia and chorea. He was unable to stand. There was pendular nystagmus in all fields of gaze, with an elliptical quality. The optic fundi were normal.

Received August 24, 1989; revision requested October 16, 1989; revision received November 9, 1989; accepted November 9, 1989.

<sup>1</sup> Department of Radiology, The University of Michigan Hospitals, 1500 E. Medical Center Dr., Ann Arbor, MI 48109-0030. Address reprint requests to S. S. Gebarski.

<sup>2</sup> The Kellogg Eye Center, Ann Arbor, MI 48109.

0195-6108/90/1103-0495  
© American Society of Neuroradiology

T1-weighted MR images at 23 months demonstrated only spinal cord, brainstem, and deep brain high white matter signal (Figs. 1A–1C). This signal indicates regions of myelination. This pattern is grossly immature for the child's chronologic age [1, 2]. T2-weighted MR images showed increased signal of peripheral white matter over that expected for the patient's age (Fig. 1D).

#### Case 2

This patient is the 28-year-old mother of patient 1. Neurologic examination was normal; T2-weighted MR images suggested asymmetric decreased signal in the basal ganglia, left more than right. As in the normal state, globi pallidi were the lowest-intensity structures in this patient's basal ganglia. There was a suggestion of increased deep white matter signal, and minimal, if any, brain atrophy (Fig. 2).

#### The Following Three Patients Are Maternal Uncles of the Proband

##### Case 3

Clinically the least severely affected of the three maternal uncles, this 20-year-old man had 4/5 lower extremity strength, which enabled

him to ambulate with the use of Canadian crutches. Horizontal nystagmus occurred with lateral gaze. Optic disk pallor was present bilaterally.

MR showed brain atrophy, with T2-weighted images demonstrating poor gray-white matter differentiation and increased white matter signal. Nearly all the patient's white matter was affected from brainstem/internal capsule through to subcortical U fibers. In addition, there was decreased signal in the thalami and basal ganglia. The putamenal signal was reduced to that of the globi pallidi (Fig. 3).

##### Case 4

This 22-year-old man had scanning but fluent speech, and could do simple calculations but could not perform other higher cognitive functions. Sensory examination was normal. There was mildly increased muscle tone and full strength in the proximal upper extremities but 0–3/5 strength distally in the upper extremities with ataxia, and 2/5 strength in the proximal lower extremities. Horizontal nystagmus was present in all fields except the primary position. Optic disk pallor was present bilaterally.

MR revealed brain atrophy, with T2-weighted images demonstrating diffusely increased white matter signal most notable in the cerebrum. Basal ganglia and thalamic signal were decreased (Fig. 4). These T2-weighted signal aberrations were similar to those in patient 3.

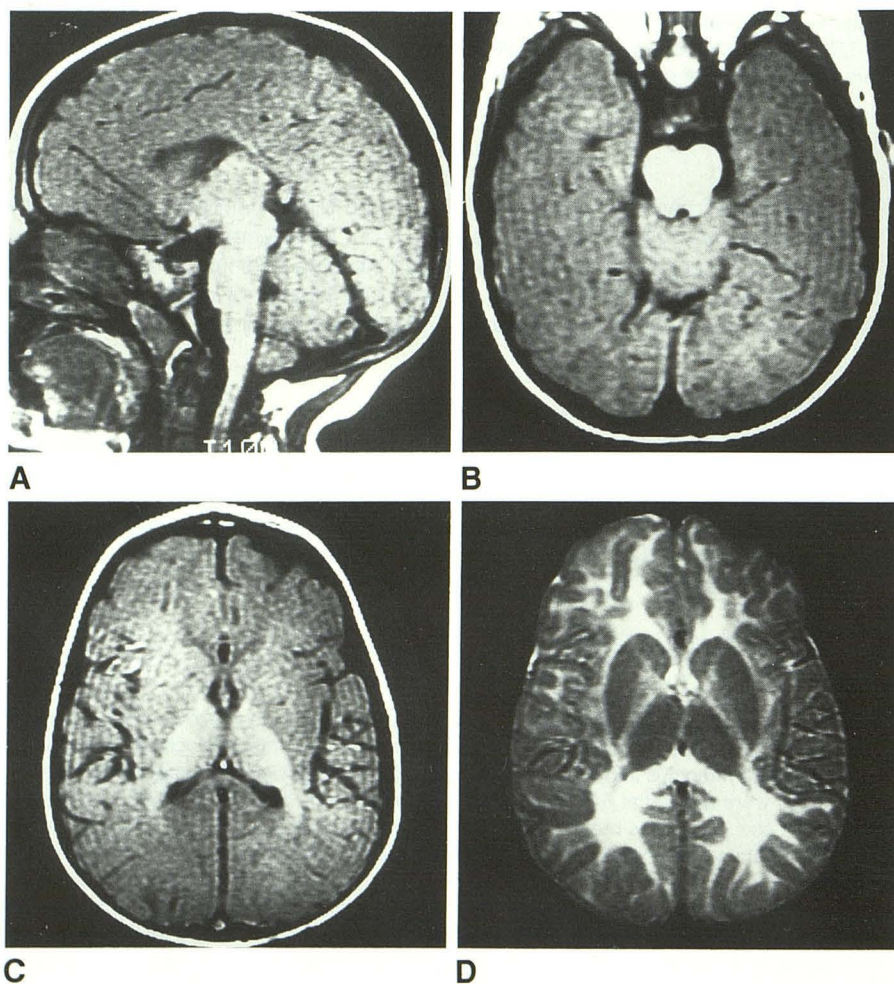
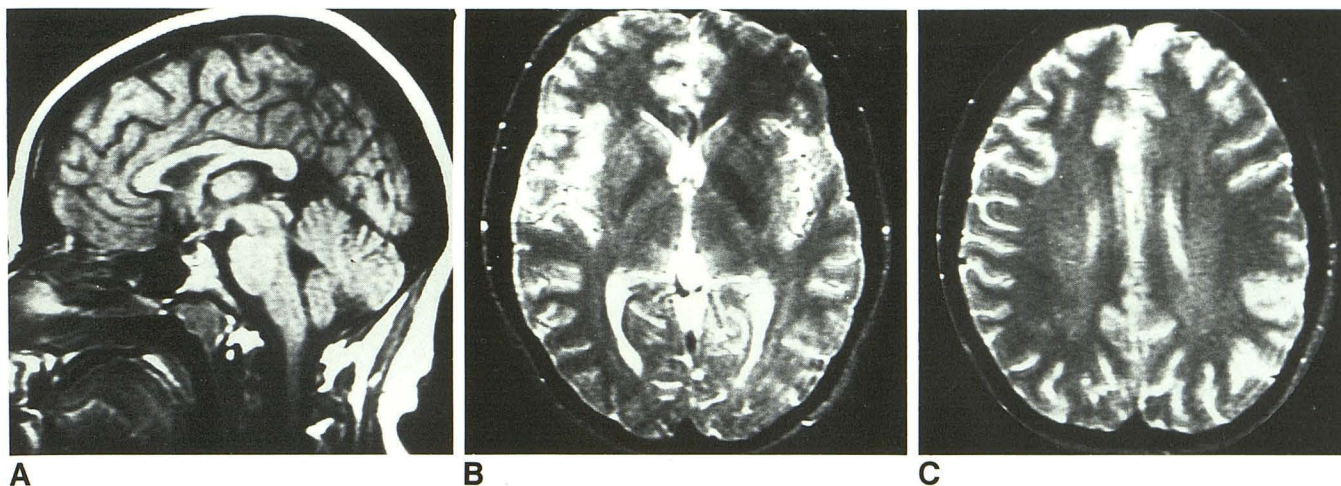


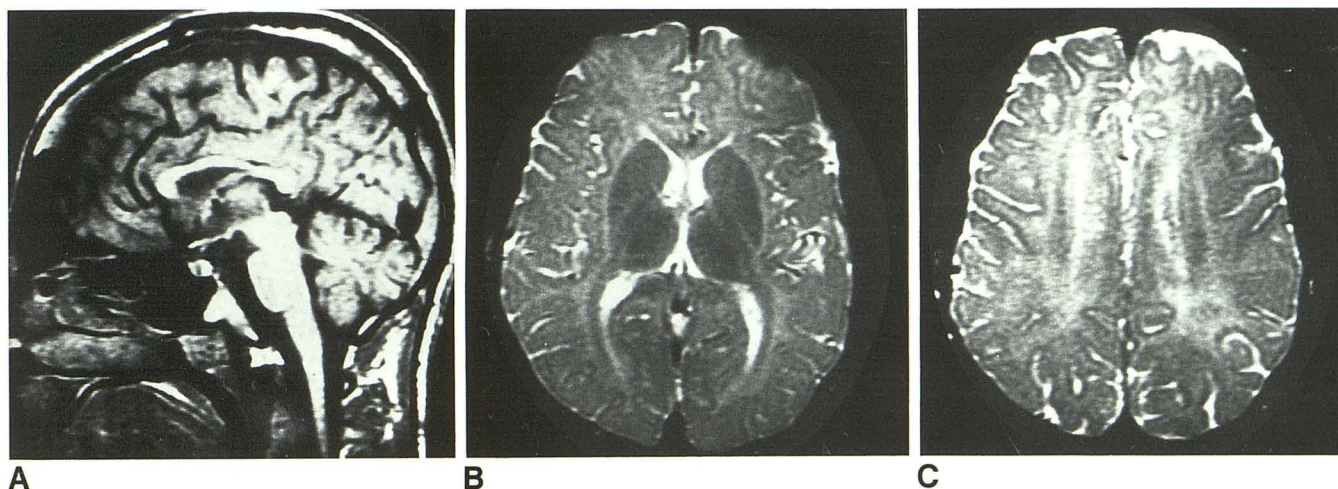
Fig. 1.—Patient 1: 23-month-old boy with severe developmental delay.

A–C, 1.5-T MR images (600/20/2). The high signal on these short TR images indicates myelination. Only the spinal cord, brainstem, internal capsule, and a small portion of centrum semiovale are myelinated. This is a grossly immature pattern for 23 months of age.

D, 1.5-T MR image (3000/90/2). Myelination on this long TR sequence is indicated by lower-signal white matter seen in internal capsules. The extensive high signal in corona radiata through to the subcortical white matter is not normal for this age. The pattern is, again, immature.



**Fig. 2.**—Patient 2: 28-year-old woman (mother of patient 1) with normal neurologic examination.  
**A**, 1.5-T MR image (600/20/2) shows minimal, if any, brain atrophy.  
**B** and **C**, 1.5-T MR images (3000/90/2) show very subtle, but suspicious, high signal in deep white matter. There is also subtle, asymmetric decreased signal in left globus pallidus. While this could be within the range of normal, it is interesting to compare it with the abnormal low signal in the basal ganglia of patients 3, 4, and 5. This signal suggests increased iron storage.



**Fig. 3.**—Patient 3: 20-year-old man (maternal uncle of patient 1) with moderate-to-severe clinical impairment.  
**A**, 1.5-T MR image (600/20/2) demonstrates brain atrophy.  
**B** and **C**, 1.5-T MR images (3000/90/2). The white matter is of diffusely higher intensity than the gray matter. Basal ganglionic and thalamic signal are markedly decreased. Putamenal, pallidal, and anterior thalamic intensity are nearly equal. This is a pathologic relationship, as the globus pallidus should have the lowest signal of these structures.

#### Case 5

This 25-year-old man, clinically the most severely affected of the three brothers, had scanning speech and was unable to perform complex calculations. Sensory examination was normal. His lower extremity strength was 0/5, and there was moderate trunk titubation, bilateral Babinski reflexes, and marked scoliosis. He required a wheelchair for locomotion. Horizontal nystagmus was present upon lateral gaze, and there was bilateral temporal optic disk pallor.

MR revealed brain atrophy, with T2-weighted images demonstrating diffuse increased white matter signal. The basal ganglia and thalami showed decreased signal (Fig. 5). These T2-weighted signal aberrations were similar to those seen in patients 3 and 4.

#### Discussion

PMD is a progressively, primarily dysmyelinating syndrome with usual clinical onset in the first months of life. Clinical findings consist of nystagmus and optic atrophy with slowly progressive pyramidal, dystonic, and cerebellar signs. Patients have abnormal brainstem, auditory, and visual somatosensory evoked potentials. PMD is usually transmitted by a recessive X-linked gene [3].

In 1970, Seitelberger [4] classified PMD into six types, differing primarily by age of clinical onset and pattern of transmission. The most common two are the classical form

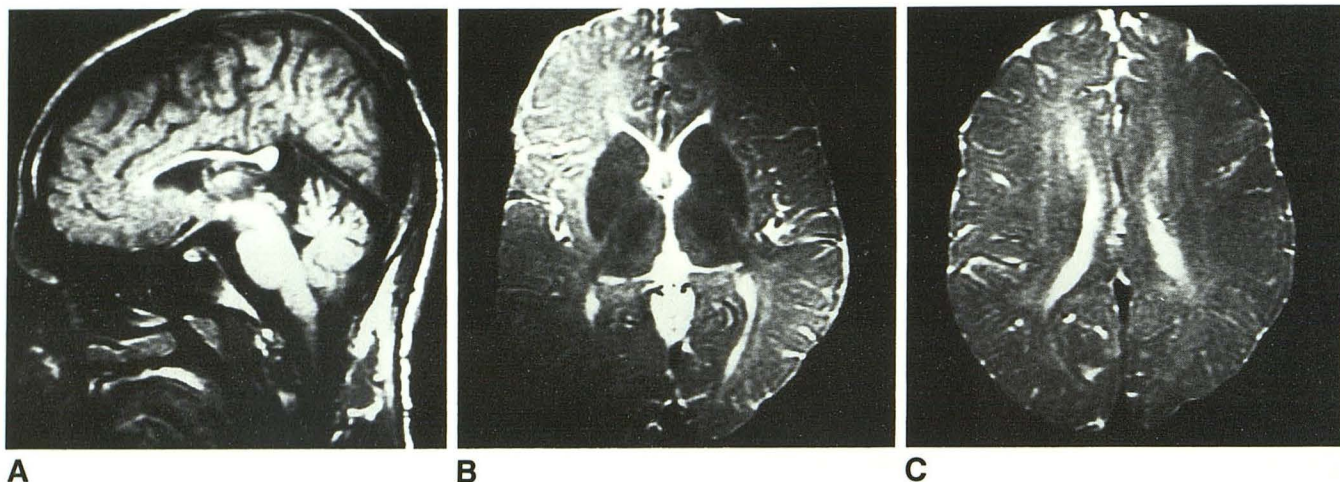


Fig. 4.—Patient 4: 22-year-old man (maternal uncle of patient 1) with severe clinical impairment.

A, 1.5-T MR image (600/20/2) demonstrates brain atrophy.

B and C, 1.5-T MR images (3000/90/2) reveal similar but slightly more marked findings than those in the long TR images of patient 3.

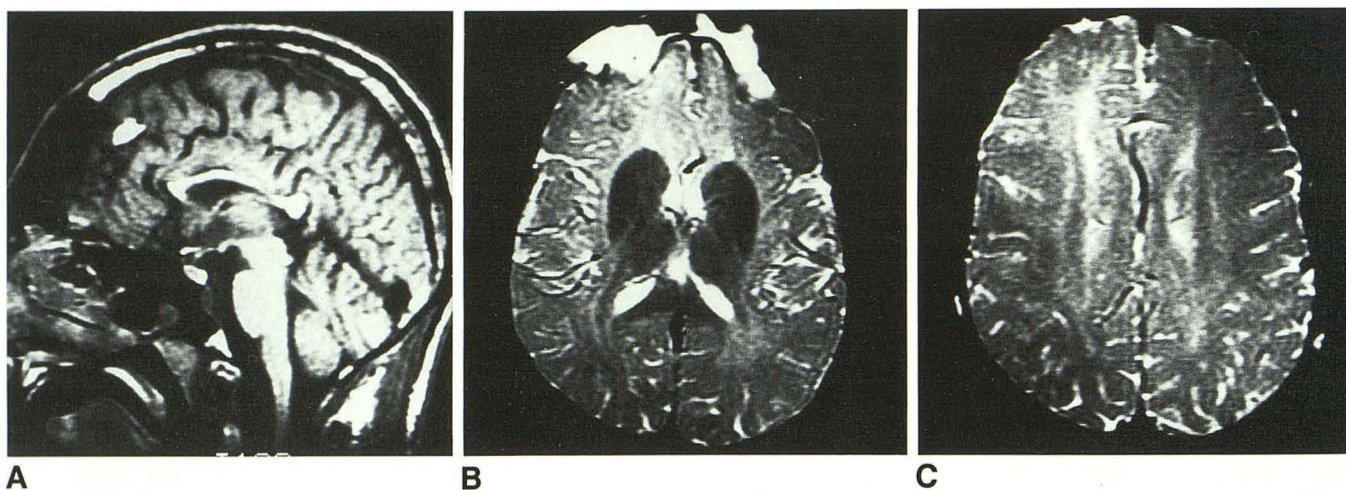


Fig. 5.—Patient 5: 25-year-old man (maternal uncle of patient 1) with very severe clinical impairment.

A, 1.5-T MR image (600/20/2) demonstrates brain atrophy.

B and C, 1.5-T MR images (3000/90/2) reveal similar but slightly more marked findings than those in the long TR images of patient 4.

and the connatal. The classical form has onset in the first months of life and is X-linked. The connatal form presents in the neonatal period, is more severe, and its pattern of inheritance is probably autosomal recessive, although this is controversial [5]. Recently, Koeppen et al. [6] reported that the CNS white matter in these patients does not synthesize proteolipid protein (PLP), and there are reduced amounts of other myelin proteins. The gene for PLP is found in the Xq-22 position. The abnormal myelination that results involves only the CNS because immunoreactive PLP is a component of CNS myelin only and is not found in the peripheral nervous system. This makes peripheral nerve biopsy of no value in PMD. Histologically, one sees a "tigroid" pattern of CNS white matter consisting of islands of myelin separated by absence of stainable myelin.

Koeppen et al. suggest that the lack of PLP is presumably responsible for the defective production of myelin. Therefore, PMD is properly termed a dysmyelinating syndrome, although some still classify it with the demyelinating disorders, as classical-type patients form some normal myelin, which they later demyelinate.

CT findings in PMD are similar to other dysmyelinating diseases. These are often normal early in the clinical course, but later reveal decreased attenuation of white matter and brain atrophy [7].

MR findings in PMD and other leukodystrophies have recently been reported [8–12]. Four patients with PMD, ages 7 to 18, demonstrated increased peripheral white matter signal compared with gray matter on T2-weighted images, which is the reverse of the normal relationship at these ages, as well

as decreased signal intensity in the basal ganglia. There was brain atrophy. Boltshauser et al. [11] used MR to study two mothers of patients (obligate carriers) and two sisters, ages 23 and 25 years, of a patient (facultative carriers). The two obligate carriers and the 23-year-old facultative carrier had multiple foci of increased signal in the white matter with frontal predominance on T2-weighted images. The 25-year-old facultative carrier had normal images. Boltshauser et al. suggested that white matter signal aberrations on MR may be used as a marker for carrier detection, potentially facilitating genetic counseling in families affected by PMD. Shimomura et al. [10] reported a 14-year-old with the MR finding of increased white matter signal with foci of normal intensity scattered within it. These were thought to be spared white matter myelin islands consistent with the neuropathologically described "tigroid" pattern, but there was no pathologic confirmation. Van der Knaap and Valk [12] interpreted MR findings from a patient with congenital PMD as representing arrest of myelination, while MR findings in two other patients with classical PMD were described as indicating both myelin arrest and slow myelin degradation. These findings suggested that the congenital form is a severe dysmyelinating process, potentially the complete failure of myelination. The more common classical form may then consist of a somewhat less severe dysmyelinating process with superimposed later demyelination of the limited normally myelinated tissue [12].

The increased white matter signal on T2-weighted images, a common finding in leukodystrophies, is presumably due to the histopathologic findings of increased white matter interstitial fluid and reduced lipid content. This pattern of increased signal is not specific for demyelination or dysmyelination. However, dysmyelinating diseases tend to result in symmetric, more uniform gross white matter involvement pathologically and on MR, while demyelinating disorders are more likely to lead to patchy asymmetric involvement [13].

The decreased basal ganglionic and thalamic signal on T2-weighted images is generally thought to be due to increased iron deposition, perhaps as a nonspecific response to degeneration and decreased neurotransmitter synthesis [8, 14, 15]. The pathologic nature of this decreased signal in our patients is best appreciated by noting that putamenal, and at times thalamic, hypointensity equaled that of the globi pallidi. The globi pallidi normally have the highest iron concentration and the lowest MR signal of these structures [14].

Brain atrophy is the end-stage of white matter disease of all types [7, 13].

In our obligate carrier (patient 2) we describe subtle, not definitely abnormal MR findings similar to, but far less severe than, the MR abnormalities in her affected brothers. These subtle findings were similar to those reported by Boltshauser et al. [11]. This woman had a normal neurologic examination.

Assuming an X-linked pattern of inheritance, variability in X chromosome inactivation may be related to the patient's age when MR findings are present. It is conceivable, therefore, that a normal MR would not exclude obligate or facultative carrier status. However, MR with a pattern similar to that reported above in a sibling of a PMD patient would be strongly suggestive of at least carrier status.

Therefore, from our limited sample and our review of the literature, we believe that MR in PMD is able to: (1) demonstrate a characteristic pattern of abnormalities such as brain atrophy, extensive symmetric increased white matter signal, and decreased basal ganglionic/thalamic signal on T2-weighted sequences (we do not know if this pattern is specific); (2) potentially detect the obligate carrier state; and (3) detect the facultative carrier state.

## REFERENCES

- McArdle CB, Richardson CJ, Nicholas DA, Mirfakhraee M, Hayden CK, Amparo EG. MR imaging. Part I. Gray white matter differentiation and myelination. *Radiology* 1987;162:223-229
- McArdle CB, Richardson CJ, Nicholas DA, Mirfakhraee M, Hayden CK, Amparo EG. MR imaging. Part II. Ventricular size and extracerebral space. *Radiology* 1987;162:230-234
- Zeman W, De Myer W, Falls HF. Pelizaeus-Merzbacher disease. *J Neuropathol Exp Neurol* 1964;23:334-354
- Seitelberger F. Pelizaeus-Merzbacher disease. In: Vinken PJ, Bruyn GW, eds. *Handbook of clinical neurology*, vol. 10. *Leucodystrophies and poliodystrophies*. Amsterdam, North Holland, 1970:150-202
- Cassidy SB, Sheehan NC, Farrell DF, Grunnet M, Holmes GL, Zimmerman AW. Congenital Pelizaeus-Merzbacher disease: an autosomal recessive form. *Pediatr Neurol* 1987;3:300-305
- Koeppen AH, Ronca NA, Greenfield EA, Hans MB. Defective biosynthesis of proteolipid protein in Pelizaeus-Merzbacher disease. *Ann Neurol* 1987;21:159-170
- Statz A, Boltshauser E, Schinzel A, Spiess H. Computed tomography in Pelizaeus-Merzbacher disease. *Neuroradiology* 1981;22:103-105
- Penner MW, Li KC, Gebarski SS, Allen RJ. MR imaging of Pelizaeus-Merzbacher disease. *J Comput Assist Tomogr* 1987;11:591-593
- Journel H, Roussey M, Gandon Y, Allaire C, Carsin M, le Marec B. Magnetic resonance imaging in Pelizaeus-Merzbacher disease. *Neuroradiology* 1987;29:403-405
- Shimomura C, Matsui A, Choh H, Funahashi M, Suzuki Y, Tsuchiya K. Magnetic resonance imaging in Pelizaeus-Merzbacher disease. *Pediatr Neurol* 1988;4:124-125
- Boltshauser E, Schinzel A, Wichmann W, Haller D, Valavanis A. Pelizaeus-Merzbacher disease: identification of heterozygotes with magnetic resonance imaging (letter). *Helv Paediatr Acta* 1987;42:337-339
- Van der Knaap MS, Valk J. The reflection of histology in MR imaging of Pelizaeus-Merzbacher disease. *AJNR* 1989;10:99-103
- Barnes DM, Enzmann DR. The evolution of white matter disease as seen on computed tomography. *Radiology* 1981;138:379-383
- Drayer BP, Burger P, Darwin R, et al. Magnetic resonance imaging of brain iron. *AJNR* 1986;7:373-380
- Drayer BP, Olanow W, Burger P, Johnson GA, Herfkens R, Riederer SJ. Parkinson plus syndrome: diagnosis using high field MR imaging of brain iron. *Radiology* 1986;159:493-498