



## Get Clarity On Generics

Cost-Effective CT & MRI Contrast Agents



FRESENIUS  
KABI

WATCH VIDEO

# AJNR

## **Hyperdense middle cerebral artery sign on CT: efficacy in detecting middle cerebral artery thrombosis.**

T A Tomsick, T G Brott, A A Chambers, A J Fox, M F Gaskill, R R Lukin, C W Pleatman, J G Wiot and E Bourekas

This information is current as of August 1, 2025.

*AJNR Am J Neuroradiol* 1990, 11 (3) 473-477  
<http://www.ajnr.org/content/11/3/473>

# Hyperdense Middle Cerebral Artery Sign on CT: Efficacy in Detecting Middle Cerebral Artery Thrombosis

Thomas A. Tomsick<sup>1</sup>  
 Thomas G. Brott<sup>2</sup>  
 A. Alan Chambers<sup>1</sup>  
 Allan J. Fox<sup>3</sup>  
 Mary F. Gaskill<sup>1</sup>  
 Robert R. Lukin<sup>1</sup>  
 Clifford W. Pleatman<sup>1</sup>  
 J. Geoffrey Wiot<sup>1</sup>  
 Eric Bourekas<sup>1</sup>

The hyperdense middle cerebral artery sign is a CT predictor of the development of a large cerebral infarct. The limits of detectability were tested in a blinded, then unblinded analysis of CT scans from 25 acute stroke patients. In the initial blinded analysis, sign detection exhibited the following mean values: sensitivity, 78.5%; specificity, 93.4%; positive predictive value, 66%; negative predictive value, 96.4%; accuracy, 91.3%. Kappa statistics analysis indicated poor interobserver agreement ( $k = .38$ ). Results of unblinded analysis were as follows: sensitivity, 69%; specificity, 94.4%; positive predictive value, 82.8%; negative predictive value, 88.7%; accuracy, 87.3%. There was fair unblinded interobserver agreement ( $k = .53$ ). Unblinded analysis had a lower false-positive frequency and did not increase the number of true-positive determinations.

We conclude that detection of the hyperdense middle cerebral artery sign on CT scans by multiple observers is a sensitive, accurate, and predictive indicator of middle cerebral artery thromboembolism.

*AJNR* 11:473-477, May/June 1990

The development of potentially effective therapies for cerebral infarction [1, 2] has provided new impetus for rapid anatomic diagnosis. Emergency cerebral angiography provides highly accurate detection of cerebrovascular occlusive disease, but if performed prior to intervention, would likely delay therapy 60 min or more at most centers. Such a time delay may blunt the potential for successful arterial recanalization and make attempts at neuronal protection less effective.

Emergency CT of the brain is already the standard first-step diagnostic procedure for patients with acute, focal neurologic deficits.

The hyperdense middle cerebral artery sign (HMCAS) has been reported in a small number of selected cases as the earliest CT sign of cerebral vascular embolism or thrombosis [3-5]. The frequency and significance of the sign in acute stroke patients are yet to be elucidated. However, no attempt to determine its true frequency and significance can be meaningful until the limits of detectability of the HMCAS are defined. We report our analysis of a study of initially blinded, then unblinded, neuroradiologic evaluations of the HMCAS in 25 acute stroke patients treated with IV tissue plasminogen activator (tPA).

## Materials and Methods

Six neuroradiologists reviewed the initial CT scans of 25 patients entered into a study of tPA in the ultraearly treatment of nonhemorrhagic acute stroke. CT scans were performed within 90 min of symptom onset. Ten-millimeter sections were obtained in all patients. Five-millimeter sections were obtained in several patients, but all determinations for the purpose of this study were based on evaluation of the 10-mm sections. Surviving patients subsequently had scans at 24 hr, 7 days, and 3 months. Infarct volume was measured by tracer-drawing an irregular region of interest on all 10-mm sections, then adding section areas. Arteriograms were obtained in 20 patients (Table 1).

Received September 14, 1989; revision requested November 16, 1989; revision received December 6, 1989; accepted December 11, 1989.

<sup>1</sup> Department of Radiology, University of Cincinnati Medical Center, 234 Goodman St., Cincinnati, OH 45267-0742. Address reprint requests to T. A. Tomsick.

<sup>2</sup> Department of Neurology, University of Cincinnati Medical Center, Cincinnati, OH 45267-0520.

<sup>3</sup> Department of Neuroradiology, University Hospital, London, Ontario N6A 5A5 Canada.

0195-6108/90/1103-0473

© American Society of Neuroradiology



TABLE 1: CT and Arteriographic Findings in 25 Patients

Patient No.	HMCAS	Angiographic Findings			No. of Days Between Stroke and Arteriogram	7-Day Infarct Volume (cm <sup>3</sup> )
		M1 Occlusion/Stenosis	M2-M4 Occlusion	ICA Stenosis (%)		
1	—	N/A	N/A	N/A	N/A	Died
2	+	N/A	N/A	N/A	N/A	287
3	—	—	—	0	4	0
4	—	—	—	0	18	28
5	—	+	—	0	1	2
6	—	—	+	50	1	11
7	+	—	+	0	5	64
8	—	—	—	0	4	36
9	—	—	+	0	1	13
10	+	+	—	100	7	227
11	—	—	+	10	7	124
12	+	+	—	100	2	125
13	—	—	—	0	20	0
14	—	N/A	N/A	N/A	N/A	Died
15	—	+	—	0	1	29
16	—	—	—	90	1	0
17	—	+	—	0	1	46
18	—	+	—	0	1	6
19	+	+	—	0	5	33
20	—	—	+	0	1	0.5
21	—	N/A	N/A	N/A	N/A	0
22	+	+	—	90	2	218
23	+	—	+	0	1	49.5
24	—	N/A	N/A	N/A	N/A	2
25	—	—	+	30	2	0

Note.—HMCAS = hyperdense middle cerebral artery sign; N/A = no arteriogram.

The six readers were initially blinded as to clinical signs, but were aware of the nature of the stroke population. Readers were asked whether the HMCAS was present (HMCAS+) or absent (HMCAS—) and, if present, on which side.

Six weeks later the readers were asked to reexamine the same scans, but were apprised of clinical signs. They were asked the same question.

A seventh neuroradiologist analyzed the 25 scans in an unblinded fashion as a reference source. He judged seven (28%) of the CT scans to be positive (Fig. 1) on the basis of the following criteria: (1) visual identification of the HMCAS; (2) arteriograph confirmation of MCA filling defect/occlusion in six of six arteriograms (no arteriogram was obtained in the seventh case); (3) CT demonstration at 24 hr and 7 days of the development of a large infarct in the appropriate MCA distribution, with diminishing density of the suspected HMCAS (7/7) (Table 1); and (4) clinical symptoms/signs in the appropriate MCA distribution (7/7).

## Results

Table 2 provides a summary of HMCAS involvement as determined by the reference neuroradiologist and the individual observers' blinded/unblinded interpretations in each of 25 patients (50 vessels).

Table 3 summarizes the individual blinded interpretations; these comprise 50 positive and 250 negative determinations: 33 true-positive and 241 true-negative readings. Mean values were as follows: sensitivity, 78.5% (33/42); specificity, 93.4% (241/258); positive predictive value, 66% (33/50); negative predictive value, 96.4% (241/250); accuracy, 91.3% (274/300).

Table 4 summarizes the individual unblinded interpretations; these comprise 35 positive and 115 negative determinations, representing 29 true-positive and 102 true-negative readings. Mean values were as follows: sensitivity, 69% (29/42); specificity, 94.4% (102/108); positive predictive value, 82.8% (29/35); negative predictive value, 88.7% (102/115); accuracy 87.3% (131/150).

Kappa statistics application is a measure of interobserver agreement. Kappa may have values of  $-1$  to  $1$ . A kappa value greater than .75 represents excellent interobserver agreement, .40 to .75 fair to good agreement, and less than .40 poor agreement [6]. In analyzing interrater agreement for this study, we found kappa = .38 for blinded evaluation, and .53 for unblinded evaluation.

Arteriographic data are included in Table 1. Eight M1 stenoses or occlusions, and seven M2, M3, or M4 [7] stenoses or occlusions were demonstrated on 20 arteriograms performed 1 to 20 days after stroke (mean, 4.2 days).

## Discussion

Attempts at emergency anatomic diagnosis of cerebrovascular occlusion and acute cerebral infarction have become increasingly important as experimental [8] and human [9] studies have shown the importance of time to the development of ischemia-induced neuronal necrosis. Transcranial Doppler sonography [10], SPECT [11], and emergency cerebral angiography [9, 12] offer promise, but each technique has significant limitations. Emergency CT is widely available,

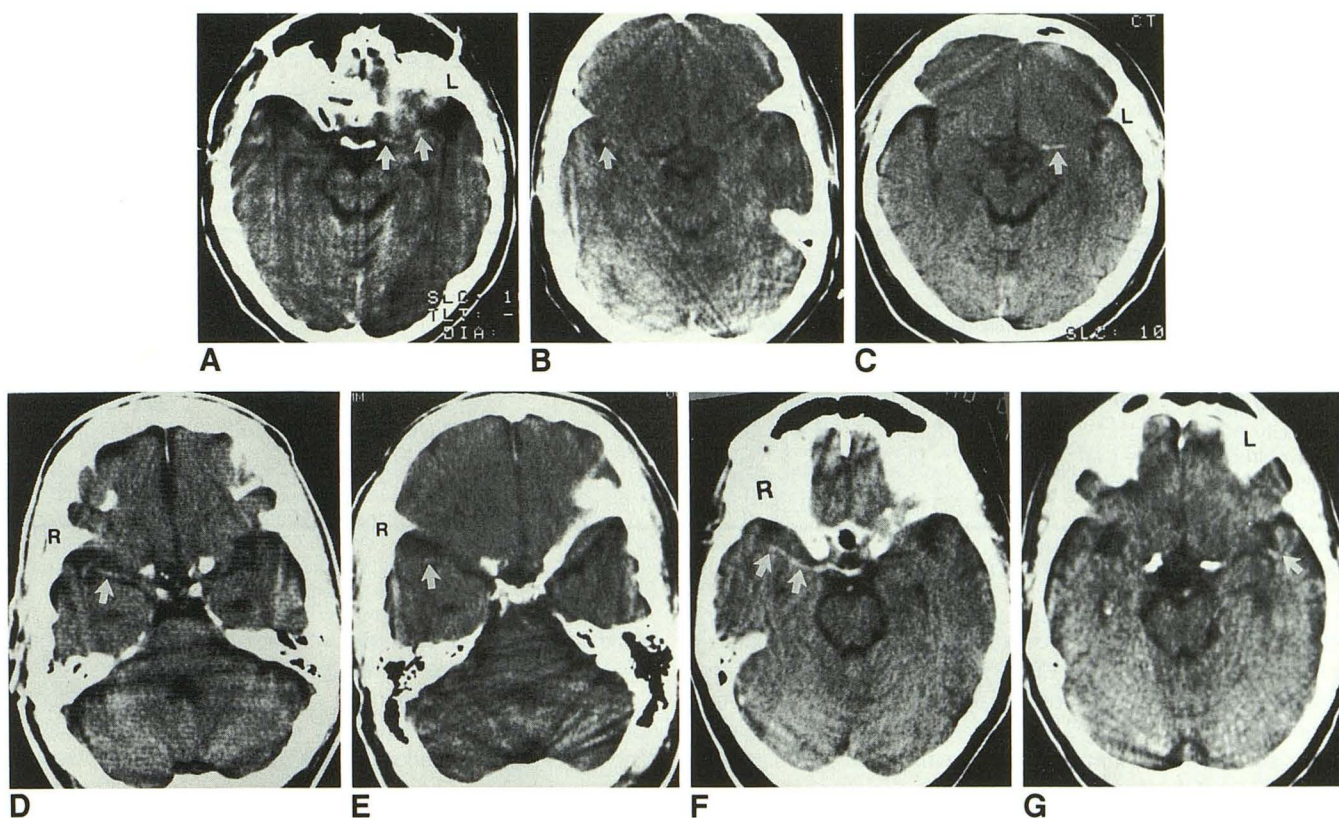


Fig. 1.—A-G, White arrows point to MCA hyperdensity in seven patients as judged by reference neuroradiologist. Patient 2 (A); patient 7 (B); patient 10 (C); patient 12 (D); patient 19 (E); patient 22 (F); patient 23 (G).

TABLE 2: Summary of Cerebral Hemisphere Involvement in 25 Patients

Patient No.	Involved Cerebral Hemisphere	MCA Hyperdensity per Reference Neuroradiologist	Blinded/Unblinded Interpretations of Six Observers					
			A	B	C	D	E	F
1	L	—	R/—	—/—	—/—	—/—	R/—	—/—
2	L	L	—/—	L/—	L/L	L/—	—/L	L/—
3	R	—	L/L	—/—	—/—	—/—	L/—	—/—
4	L	—	—/—	—/—	—/—	—/—	—/—	—/—
5	L	—	—/—	—/—	—/—	—/—	—/—	—/—
6	L	—	—/—	—/—	—/—	—/—	—/—	L/L
7	R	R	—/R	R/R	R/—	—/—	R/R	—/—
8	L	—	—/—	—/L	—/—	—/—	—/—	—/L
9	L	—	—/—	—/—	L/L	—/—	—/—	—/—
10	L	L	L/L	L/L	L/L	L/L	L/L	L/L
11	R	—	—/—	—/—	—/—	—/—	—/—	—/—
12	R	R	R/R	R/R	R/R	R/R	R/R	R/R
13	R	—	—/—	—/—	—/—	—/—	—/—	—/—
14	L	—	—/—	L/—	—/—	—/—	—/—	—/—
15	R	—	—/—	—/—	—/—	L/—	—/—	L/—
16	L	—	R/—	R/—	—/—	—/—	R/—	—/—
17	R	—	—/—	—/—	—/—	—/—	—/—	—/—
18	L	—	—/—	—/—	—/—	—/—	—/—	—/—
19	R	R	—/R	R/—	R/R	—/—	R/R	—/—
20	R	—	—/—	—/—	L/—	—/—	—/—	—/—
21	L	—	—/—	R/—	—/—	—/—	R/—	—/—
22	R	R	R/R	R/R	R/R	R/R	R/R	R/R
23	L	L	L/L	L/L	L/—	L/—	L/L	—/—
24	R	—	R/—	—/—	—/R	—/—	—/—	—/—
25	L	—	—/—	R/—	—/—	—/—	—/—	—/—
Total		7	8/7	11/6	9/7	6/3	10/7	6/5

Note.—Presence (R or L) or absence (—) of HMCAS involvement.



TABLE 3: Summary of Individual Blinded Interpretations and Results\*

	A	B	C	D	E	F
Sensitivity (%)	4/7 (57.1)	7/7 (100)	7/7 (100)	5/7 (71.4)	6/7 (85.7)	4/7 (57.1)
Specificity (%)	39/43 (90.6)	39/43 (90.6)	41/43 (95.3)	42/43 (97.6)	39/43 (90.7)	41/43 (95.3)
Positive predictive value (%)	4/8 (50.0)	7/11 (63.6)	7/9 (77.7)	5/6 (83.3)	6/10 (60.0)	4/6 (66.6)
Negative predictive value (%)	39/42 (92.8)	39/39 (100)	41/41 (100)	42/44 (95.4)	39/40 (97.5)	41/44 (93.1)
Accuracy (%)	43/50 (86.0)	46/50 (92.0)	48/50 (96.0)	47/50 (94.0)	45/50 (90.0)	45/50 (90.0)

\* Based on 50 vascular distributions.

TABLE 4: Summary of Individual Unblinded Interpretations and Results\*

	A	B	C	D	E	F
Sensitivity (%)	6/7 (85.7)	5/7 (71.4)	5/7 (71.4)	3/7 (42.8)	7/7 (100)	3/7 (42.8)
Specificity (%)	17/18 (94.4)	17/18 (94.4)	16/18 (88.9)	18/18 (100)	18/18 (100)	16/18 (88.9)
Positive predictive value (%)	6/7 (85.7)	5/6 (83.3)	5/7 (71.4)	3/3 (100)	7/7 (100)	3/5 (60)
Negative predictive value (%)	17/18 (94.4)	17/19 (89.5)	16/18 (88.9)	18/22 (81.8)	18/18 (100)	16/20 (80)
Accuracy (%)	23/25 (92)	23/25 (92)	21/25 (84)	21/25 (84)	25/25 (100)	19/25 (76)

\* Based on 25 vascular distributions.

can be performed rapidly on acutely ill patients, and will likely continue to precede other diagnostic procedures for acute CNS emergencies for the foreseeable future. Therefore, detection of the HMCAS by CT affords the opportunity for early diagnostic vascular information with minimal delay in patient evaluation and therapy.

This study indicates that reliable detection of the HMCAS on an emergency 1-cm-slice CT scan of acutely ill stroke patients is difficult. Interrater agreement is poor to fair as assessed with the kappa statistic. Nonetheless, attention to the presence or absence of the sign can be useful, particularly in the setting of a stroke therapy study. There was total agreement on three of the seven patients with the sign (Table 2). For these three patients, the subsequent mean infarct volume was 190 cm<sup>3</sup> vs 49 cm<sup>3</sup> for the 18 patients without the HMCAS (Table 1). The HMCAS in these three patients involved the M1 segment proximally or entirely (Figs. 1C, 1D, 1F). Of the seven patients with the sign, six had post-tPA angiograms: four of these had residual M1 segment MCA occlusions, and the other two had residual M2 or M3 segment occlusions; two of the six had ipsilateral ICA occlusions, one had ipsilateral 90% ICA stenosis, and two of the remaining three had atrial fibrillation.

Various factors could lead to inaccurate determinations regarding the sign: (1) partial volume effects—an HMCAS not suspected on 10-mm images may be detected on 3- or 5-mm sections; (2) vessel calcification; (3) anatomic variation—a vessel that traverses vertically through an entire section thickness will appear denser than one that passes obliquely or parallel to it on the opposite side; and (4) scan artifacts, including motion.

Individual readers vary in their sensitivity to the sign. The number of blinded positive determinations by individual interpreters ranged from six to 11 (mean, 8.5). Subsequent unblinded positive determinations ranged from three to seven (mean, 5.8). It is of interest that of 17 initial blinded false-positive determinations, 13 were on the side opposite to the clinically involved vessel (Table 2). Kappa statistics analysis

of the data indicates poor blinded ( $k = .38$ ) and fair unblinded ( $k = .53$ ) interobserver correlation.

A positive determination by one reader alone is open to question. Table 2 shows that sporadic single HMCAS+ blinded readings will occur in unaffected patients. However, agreement of four, five, or all six observers was only seen in affected individuals. This tendency persisted in a less marked fashion among the unblinded interpreters. This indicates that some cases are equivocal; but with consensus opinion for the HMCAS, predictive value is high (i.e., some cases of HMCAS are dramatic and clear-cut).

A negative determination may have every bit as great an impact if unaffected patients are shown to follow a more benign course or respond differently to a treatment than affected patients [13]. The likelihood of recognizing an unaffected patient (specificity) is quite high for both blinded and unblinded observers (93.4 vs 94.4%). The high likelihood that a negative determination indicates an unaffected patient (negative predictive value = 96.4% blinded vs 88.7% unblinded), as well as the high specificity, places greater confidence in a negative interpretation. How accurately does absence of the sign exclude MCA occlusion? In a previous study we discovered 13 large infarcts in the MCA distribution in 50 acute stroke patients [14, 15]. Six (46%) were HMCAS+ and seven HMCAS-, suggesting a high false-negative rate for the sign as an absolute indicator of MCA occlusion.

In 18 HMCAS- patients in the current study, 14 had arteriograms. Four arteriograms showed distal incomplete, likely recanalizing, M1 occlusion, and five others had occlusion beyond the M1 segment. Two HMCAS- patients developed infarcts of 28 and 36 cm<sup>3</sup> at 7 days, but had no occlusive changes at arteriography on days 4 and 18, respectively. Of four HMCAS- patients without arteriograms, two developed large infarcts compatible with ICA or MCA occlusion and died and two developed small central infarcts of volumes not usually associated with MCA occlusion [16, 17]. Clearly, absence of the HMCAS does not exclude MCA thromboembolism.



We conclude that: (1) with a 1-cm slice thickness, the frequency of the HMCAS in this stroke population could be as high as 28% (seven of 25 as determined by retrospective analysis of scan and clinical data), or as low as 12% (three of 25 as determined by total agreement of seven observers); (2) interobserver agreement on the presence or absence of the sign is poor blinded and fair unblinded; and (3) consensus agreement of visual detection of the HMCAS in individual patients is sensitive, predictive, and accurate for detection of MCA thrombus.

## REFERENCES

1. del Zoppo G, Ferbert A, Otis S, et al. Local intraarterial fibrinolytic therapy in acute carotid territory stroke. *Stroke* **1988**; 19:307-312
2. Brott TG, Haley EC, Levy DE, et al. Tissue plasminogen activator (tPA) as very early therapy for cerebral infarction. *Circulation* **1987**; 76 (Suppl):142
3. Gacs G, Fox AJ, Barnett HJM, Vinuela F. CT visualization of intracranial arterial thromboembolism. *Stroke* **1983**; 14:756-762
4. Pressman BD, Tourje EJ, Thompson JR. An early CT sign of ischemic infarction: increased density in a cerebral artery. *AJNR* **1987**; 8:645-648
5. Schuierer G, Huk W. The unilateral hyperdense middle cerebral artery: an early CT-sign of embolism or thrombosis. *Neuroradiology* **1988**; 30: 120-122
6. Fleiss J. *Statistical methods for rates and proportions*, 2nd ed. New York: Wiley, **1981**:211-236
7. Gibo H, Carver CC, Rhoton AL, Lenkey C, Mitchell R. Microsurgical anatomy of the middle cerebral artery. *J Neurosurg* **1981**; 54:151-169
8. Boisvert DP, Gelb AW, Tang C, Lam AM, Mielke B, Dowman R. Brain tolerance to middle cerebral artery occlusion during hypotension in primates. *Surg Neurol* **1989**; 31:6-13
9. Fieschi C, Argentino C, Lenzi GL, Sacchetti ML, Toni D, Bozzao L. Clinical and instrumental evaluation of patients with ischemic stroke within the first six hours. *J Neurol Sci* **1989**; 91:311-323
10. Zanette EM, Fieschi C, Bozzao L, et al. Comparison of cerebral angiography and transcranial Doppler sonography in acute stroke. *Stroke* **1989**; 20:899-903
11. Brott TG, Gelfand MJ, Williams CC, Spilker JA, Hertzberg VS. Frequency and patterns of abnormality detected by iodine-123 amine emission CT after cerebral infarction. *Radiology* **1986**; 158:729-734
12. Bozzao L, Fantozzi LM, Bastianello S, Bozzao A, Fieschi C. Early collateral blood supply and late parenchymal brain damage in patients with middle cerebral artery occlusion. *Stroke* **1989**; 20:735-740
13. Theron J, Courtheoux P, Casasco A, et al. Local intraarterial fibrinolysis in the carotid territory. *AJNR* **1989**; 10:753-765
14. Tomsick T, Brott T, Olinger C, et al. Dense MCA in experimental drug treatment. *AJNR* **1988**; 9:1037 (abstr)
15. Tomsick T, Brott T, Olinger C, Barsan W, Spilker J, Adams H. Hyperdense middle cerebral artery sign: incidence and quantitative significance. *Neuroradiology* **1989**; 31:312-315
16. Olsen TS, Skriver EB, Herning M. Cause of cerebral infarction in the carotid territory. Its relation to the size and the location of the infarct and to the underlying vascular lesion. *Stroke* **1985**; 16:459-466
17. Saito I, Segawa H, Shiokawa Y, Taniguchi M, Tsutsumi K. Middle cerebral artery occlusion: correlation of computed tomography and angiography with clinical outcome. *Stroke* **1987**; 18:863-868