



Providing Choice & Value
Generic CT and MRI Contrast Agents

**FRESENIUS
KABI**

CONTACT REP

AJNR

**Automated percutaneous biopsy in postoperative
diskitis: a new method.**

G Onik, Y L Shang and J C Maroon

AJNR Am J Neuroradiol 1990, 11 (2) 391-393

<http://www.ajnr.org/content/11/2/391.citation>

This information is current as
of July 20, 2025.

Automated Percutaneous Biopsy in Postoperative Diskitis: A New Method

Gary Onik,¹ Yulin Shang, and Joseph C. Maroon

Postoperative disk space infection or diskitis (POD) is a relatively uncommon but debilitating complication of disk surgery [1, 2], and despite the current level of knowledge, its reasonably early clinical diagnosis is still difficult to make [3, 4]. Once POD is clinically suspected and the erythrocyte sedimentation rate is shown to be elevated, radiologic studies may not demonstrate the early changes or at least may not differentiate it from postoperative changes [1]. Although percutaneous fine needle aspiration biopsy sampling of the suspected disk space in POD has some strong advocates, the small samples obtained have raised doubts as to the accuracy of negative bacteriologic results [5]. We have recently used a new automated percutaneous biopsy technique that allowed large specimens to be obtained successfully with minimal risk of morbidity.

Materials and Methods

Once POD is clinically suspected, an automated percutaneous biopsy may be conducted immediately in accordance with the following procedure. In the lateral decubitus position, under local anesthesia with fluoroscopic guidance, an 18-gauge hubless trocar is placed down to the disk space at an angle of approximately 30–45°. The entry point is approximately 8–12 cm lateral to the posterior middle line. The position of the trocar is confirmed by anteroposterior and lateral views on fluoroscopy. The trocar is then advanced into the center of the disk, and then over this is placed a 2.8-mm cannula, which is advanced against the disk margin. The cannula is confirmed to be against the anulus on the oblique view. Then the trephine is introduced over the trocar through the cannula and the anulus is incised.

The Nucleotome (Surgical Dynamics, Inc., San Leandro, CA) is then placed through the cannula and confirmed to be in the center of the disk (Fig. 1). Multiple aspiration biopsies of the disk space are obtained without removing the cannula from the disk. The adequacy of the sample obtained is assessed by watching the aspiration line of the instrument.

Using the apparatus and technique just described, we biopsied two patients with the clinical syndrome of postoperative diskitis. The first patient was a 45-year-old man who had a laminectomy and microdisectomy at both L5–S1 and L4–L5. Approximately 4 months

after these procedures he developed severe back pain with elevated sedimentation rate. An MR scan revealed the typical changes of diskitis with increased intensity of the adjacent endplates on T2-weighted images with destruction of the endplates (Fig. 2). The disk space was biopsied with the Nucleotome; a culture revealed *Staphylococcus aureus*.

The second patient had basically the same history with evidence of diskitis on both CT (Fig. 3) and MR. Culture from the Nucleotome-aspirated material showed *Staphylococcus epidermidis*. Both patients made a gradual recovery on antibiotic therapy.

Discussion

The incidence of POD reported in the last decade ranged approximately from 0.7 to 2.4% [2, 6, 7]. Options for obtaining a sample from a suspected disk include fine needle aspiration biopsy, trephine biopsy with a Craig needle, and open operative biopsy. The advantage of aspiration needle biopsy is that the size of the needle is small and there is consequently less trauma in performing the procedure. The drawback is that the small size of these needles makes it more difficult to get an adequate sample, particularly if there is no pus to be aspirated [8]. This may make the results less reliable than those obtained from a more extensive biopsy.

The advantage of the trephine biopsy with a Craig needle is that its larger size (up to 6 mm in diameter) allows one to obtain a larger sample than that provided by the needle aspiration [8]. Moreover, this procedure can be done under local anesthesia with minimal morbidity. However, even with this larger instrument, it may still be difficult to obtain an adequate sample of solid disk material. In addition, the large size of the cannula and trephine makes the approach to the L5–S1 space difficult, which precludes this approach in a large percentage of cases. Finally, although this method allows one to obtain a larger sample for diagnosis, it holds no potential for débridement and possible treatment.

An open biopsy has the obvious advantage of providing an adequate tissue sample while allowing débridement of the disk space. The disadvantage of this method includes the obvious problems of an open operation with general anes-

Received December 8, 1988; revision requested February 7, 1989; revision received August 29, 1989; accepted August 29, 1989.

This work was supported by the Allegheny-Singer Research Institute, Pittsburgh, PA.

¹ All authors: Department of Neurosurgery, Allegheny General Hospital, Allegheny-Singer Research Institute, 420 E. North Ave., East Wing, Suite 302, Pittsburgh, PA 15212. Address reprint requests to G. Onik.

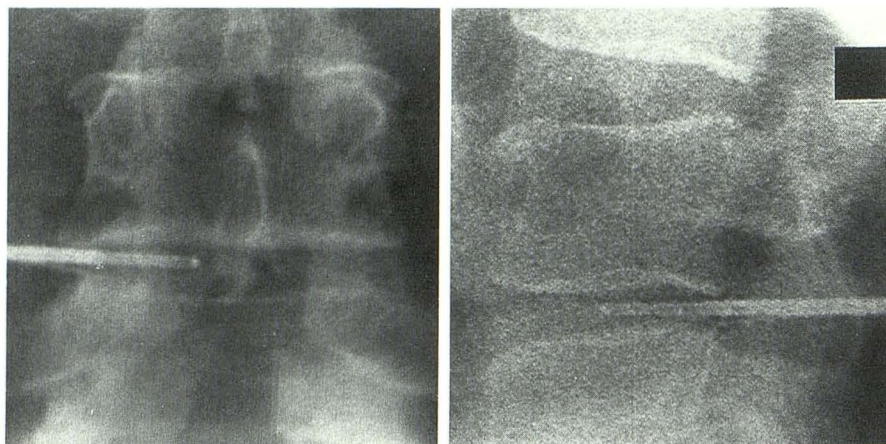


Fig. 1.—A and B, Anteroposterior (A) and lateral (B) fluoroscopic images show Nucleotome in L4-L5 disk space in patient 2.

A

B

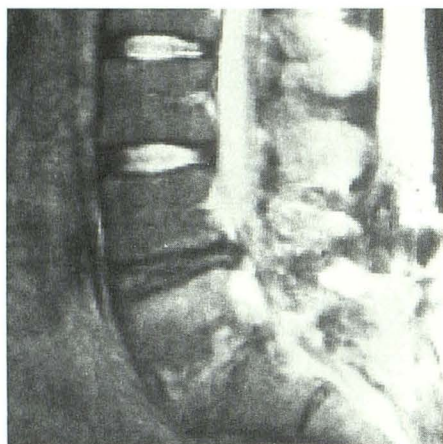

Fig. 2.—Sagittal MR scan, 2100/90 (TR/TE), shows destruction of L5-S1 endplates, with areas of hyperintensity adjacent to endplate.

2

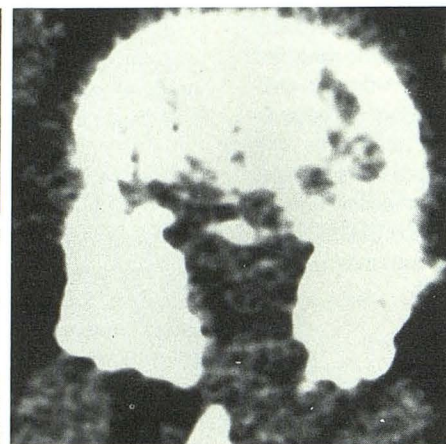

Fig. 3.—CT scan from patient 2 shows post-operative changes of epidural fibrosis and permeative destructive changes in L5 vertebral body endplate.

3

thetia and the attendant trauma associated with this open approach, particularly in patients who have had previous surgery or who have epidural fibrosis.

Automated aspiration biopsy of the disk space with the Nucleotome may be the best alternative for this problem [9–11]. The procedure can be done under local anesthesia, and although the size of the instruments (2.8 mm for the cannula) is markedly smaller than that of the Craig needle, an adequate sample can still be obtained. Experience with disk aspirations in noninfected disks for the treatment of lumbar disk herniations has shown that up to 7 g of disk material can be aspirated, raising the possibility that this method, besides providing an adequate sample with minimal morbidity, might also allow débridement and decompression of the infected disk. Finally, with the use of a curved cannula, the method can be applied to the L5–S1 level. For these reasons this is now our standard method for biopsying a disk space. Since these patients were biopsied, we have used the method successfully in three other patients, two of whom had primary diskitis. The only patients on whom we would not use this method are those with a progressive neurologic deficit and

epidural abscess. For these patients, an open procedure is preferable.

The safety of the procedure lies in the fact that it is done under local anesthesia, which greatly reduces the chance for nerve root injury. The instrument itself has a blunt end, which makes it extremely difficult to push through the opposite anulus. The instrument is designed to aspirate only semisolid material into its side port. It therefore cannot cut the anulus, and once placed within the disk, cannot reach surrounding structures such as the thecal sac and great vessels. The safety of this method has been demonstrated in its application to the treatment of herniated lumbar disks [9–11].

Although our experience with these two cases does not provide any statistically significant results, the following conclusions seem to be apparent.

1. Because postoperative diskitis may be difficult to diagnose, an effective percutaneous biopsy can facilitate the diagnosis.

2. The early administration of effective antibiotics, depending on the bacterial evaluation, is very important in the treatment of the infective disease. Compared with an open pro-

cedure, the automated discectomy technique can provide an equal specimen with greater safety and can allow early histologic and bacteriologic diagnosis.

3. If early surgical involvement proves to be a better treatment for POD, automated discectomy has the potential to allow débridement of the disk space.

REFERENCES

1. Dall BE, Rowe DE, Odette WG, Batts DH. Postoperative discitis—diagnosis and management. *Clin Orthop* **1987**;224:138–146
2. El-Gindi S, Aref S, Andrew J. Infection of intervertebral discs after operation. *J Bone Joint Surg* **1976**;58B:114–116
3. Heller RM, Szalay EA, Green NE, Horev GD, Kirchner SD. Disc space infection in children: magnetic resonance imaging. *Radiol Clin North Am* **1988**;26:207–299
4. Teplick JG, Haskin ME. Computed tomography of the postoperative spine. In: Taveras JM, Ferrucci JT, eds. *Radiology: diagnosis/imaging/intervention*, vol. 3. Philadelphia: Lippincott, **1986**:Ch. 108, 1–10
5. Taylor TKF, Dooley BJ. Antibiotics in the management of postoperative disc space infections. *Aust NZ J Surg* **1978**;48:74–75
6. Wilson DH, Harbaugh R. Lumbar discectomy: a comparative study of microsurgical and standard technique. In: Hardy R, ed. *Lumbar disc disease*. New York: Raven Press, **1982**:147–156
7. Lindholm TS, Pylkkanen P. Discitis following removal of intervertebral disc. *Spine* **1982**;7:618–622
8. Bard M, Laredo JD. Percutaneous biopsy of musculoskeletal lesions. In: *Interventional radiology in bone and joint*. New York: Springer-Verlag, **1988**:3–50
9. Onik G, Helms CA, Ginsburg L, Hoaglund FT, Morris J. Percutaneous lumbar discectomy using a new aspiration probe. *AJNR* **1985**;144:1137–1140
10. Onik G, Helms CA, Ginsberg L, Hoaglund FT, Morris J. Percutaneous lumbar discectomy using a new aspiration probe: porcine and cadaver model. *Radiology* **1985**;155:251–252
11. Maroon JC, Onik G. Percutaneous automated discectomy: a new method for lumbar disc removal. *J Neurosurg* **1987**;66:143–146