



Providing Choice & Value

Generic CT and MRI Contrast Agents



**FRESENIUS
KABI**

CONTACT REP

AJNR

**Extracranial Complications of Cerebrospinal
Fluid Shunt Function in Childhood
Hydrocephalus**

F. Reed Murtagh, Robert M. Quencer and Catherine A. Poole

AJNR Am J Neuroradiol 1980, 1 (4) 301-304

<http://www.ajnr.org/content/1/4/301>

This information is current as
of July 23, 2025.

Extracranial Complications of Cerebrospinal Fluid Shunt Function in Childhood Hydrocephalus

F. Reed Murtagh¹
Robert M. Quencer²
Catherine A. Poole²

There were 112 separate hospital evaluations in 84 patients for suspected shunt malfunction; 96 evaluations were of ventriculoperitoneal shunts, 13 were of ventriculoatrial shunts, and three were of both types of shunts. In 45 (47%) of 96 ventriculoperitoneal shunts, complications eventually led to surgical revision; 20 (44%) of these were problems of the peritoneal end and therefore peculiar to this type of shunt. Peritoneal end problems included tubing disconnection, bowel obstruction, perforation, and abdominal cerebrospinal fluid pseudocyst. Of the 13 ventriculoatrial shunts, 10 (79%) required revision; eight (61%) of these were due to problems of the atrial end. These problems included relative shortening of the tubing due to patient growth, superior vena cava thrombosis, and disconnection. Ventriculoperitoneal shunts were used most frequently and had a lower complication rate (47%). Ventriculoatrial shunts were used less often and had a higher complication rate (79%) and more serious problems.

Cerebrospinal fluid shunting systems are far from trouble-free devices, often requiring frequent surgical revision to assure continued function. In an earlier study [1], we detailed evaluation of the proximal part (ventricular end) of shunt systems by computed tomography (CT), which has become very useful in the management of pediatric hydrocephalus [2-6]. In this paper, we deal with radiologic evaluation of extracranial parts (distal ends) of shunt systems and the important complications of each of the principal shunt types.

Materials and Methods

There were 112 separate hospital evaluations of shunt function status in 84 pediatric patients under age 13 years at University of Miami School of Medicine/Jackson Memorial Hospital. All 112 evaluations involved a CT scan of the brain and routine radiography of the skull, chest, and, in ventriculoperitoneal shunts, the abdomen. Other means of radiographic evaluation of shunt function included radionuclide cisternography/shuntography (four cases) and ventriculography (one case).

In all cases, admission for shunt evaluation was predicated on some change in the patient's status that signaled possible increased intracranial pressure and prompted the question of shunt patency [1]. Shunt malfunction was recognized by papilledema, increasing head circumference, seizures, decreasing levels of consciousness, enlarged or enlarging ventricles on CT scan, difficulty pumping the small subcutaneous part of the shunt located under the scalp, or, usually, a combination of several of these criteria.

Results

Of the 112 shunt evaluations, 13 (12%) were of ventriculoatrial shunts and 96 (86%) were of ventriculoperitoneal shunts. In three instances (2%), the patient had both types of shunts.

Received December 7, 1979; accepted after revision March 31, 1980.

¹Department of Radiology, University of South Florida College of Medicine, 12901 N. 30th St., Box 17, Tampa, FL 33612. Address reprint requests to F. R. Murtagh.

²Department of Radiology, University of Miami School of Medicine, Miami, FL 33812.

This article appears in July/August 1980 *AJNR* and October 1980 *AJR*.

AJNR 1:301-304, July/August 1980
0195-6108/80/0104-0301 \$00.00
© American Roentgen Ray Society

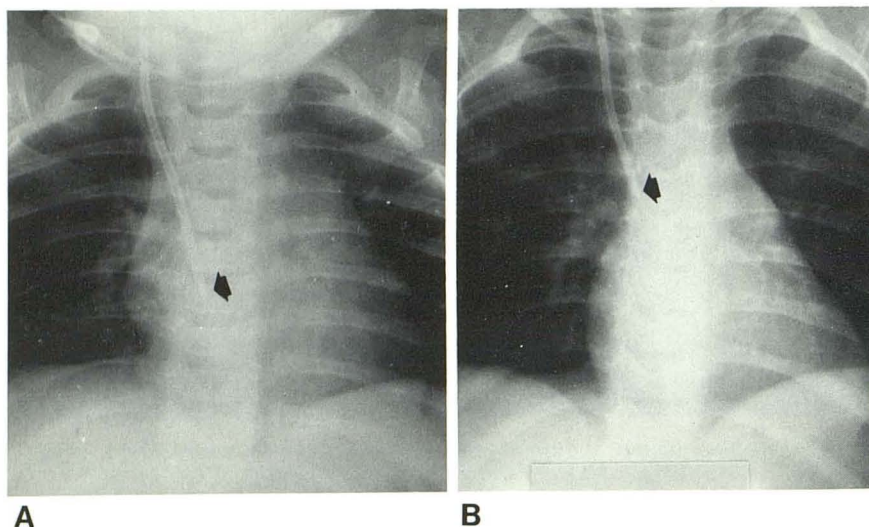


Fig. 1.—Case 1, 3-month-old infant with aqueductal stenosis and ventriculoatrial shunt. **A**, Tip position in atrium is excellent (arrow). **B**, 8 months later. Growth of child resulted in withdrawal of shunt tip (arrow) from atrium. Surgical lengthening was necessary.

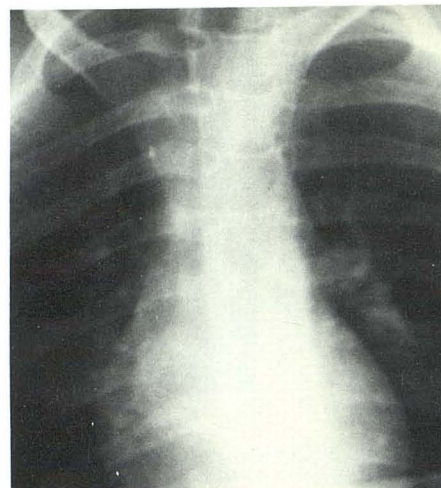


Fig. 2.—Case 2, 8-year-old boy with ventriculoatrial shunt with opacified tip (arrow) in superior vena cava. Tip was held firm in thrombosed superior vena cava and could not be removed.

TABLE 1: Hospital Evaluations for Shunt Malfunction

Finding	Type of Shunt, No. (%)	
	Ventriculoperitoneal	Ventriculoatrial
No complications	51 (53)	3 (21)
Complications leading to surgical revision:		
Proximal (ventricular) end	19	1
Infection	6	1
Distal end (peritoneal or atrial):		
Shortened tubing	8	4
Disconnected tubing	4	0
Thrombosis	0	4
Omental clogging	3	0
Perforated viscus	3	0
Bowel obstruction	1	0
Tubing migrated to nonabsorbative area	1	1
Subtotal	20	8
Total complications	45 (47)	10 (79)
Total evaluations*	96	13

* There was a total of 112 evaluations. There were no complications in the three instances of coexisting ventriculoperitoneal and ventriculoatrial shunts, yielding an overall complication rate of 49%.

The 112 shunt evaluations were grouped according to the shunt complications that led to surgical revision and that were peculiar to each of the two types of shunt (table 1). Of the 13 ventriculoatrial shunts evaluated, there were 10 complications (79%). Of the 96 ventriculoperitoneal shunts evaluated, 45 cases (47%) had complications. The three cases with both ventriculoatrial and ventriculoperitoneal shunts did not need surgical revision. In each case, at least one of the shunts was working well enough to drain the ventricular system.

Ventriculoatrial Shunts

Ventriculoatrial shunt complications mostly involved the distal (atrial) end (eight of 10 complications). One case of

ventricular end malfunction and one case of infection were excluded, since they could as easily have occurred in ventriculoperitoneal shunts and were not peculiar to the ventriculoatrial form. Routine chest radiography was used to determine the length and position of the atrial end, resulting in the discovery of shortened tubing in half of the cases (four of eight complications). As the pediatric patient grows, the constant length of the vascular tubing results in progressive elevation of the distal tip out of the region of the atrium, which is the optimal location for successful drainage of cerebrospinal fluid [7, 8]. Figure 1A shows a chest film of case 1, a 3-month-old child with functioning shunt; 8 months later, the tip of the atrial end was above the level of the atrium and the shunt functioned marginally (fig. 1B). The shunt pumped fairly well, but some ventricular enlargement was present on CT. The shunt tubing was lengthened surgically in this case, after which the patient did well. Lengthening of the atrial end is considered necessary on a prophylactic basis if the tubing becomes too short with growth of the child, and replacement of the distal end is necessary if it flips out of the atrium or kinks on itself [9].

One of the most serious complications of ventriculoatrial shunt, thrombosis of the superior vena cava [10], was found in four of our evaluations. Case 2, an older child with a ventriculoatrial shunt (fig. 2), had enlarged ventricles on CT and the shunt pump depressed with some difficulty, suggesting distal shunt blockage. Attempted injection of contrast medium (Conray) toward the distal end met with obstruction; at surgical revision, the distal end was fibrosed in the superior vena cava and had to be left in place. The ventricular end was connected to a new peritoneal end shunt and the patient did well. Other potentially serious complications—disconnection of the tubing, perforation of neighboring organs [11], and infection—were not encountered in our series. Our complication rates compare favorably with other series [12].

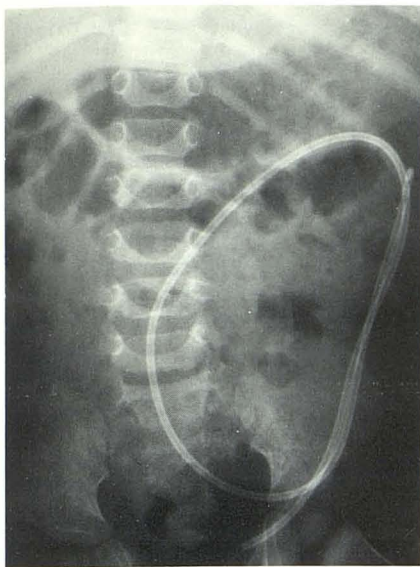


Fig. 3.—Case 3, 9-year-old boy with nonfunctioning ventriculoperitoneal shunt. Disconnected peritoneal end floats free in peritoneal cavity and required surgical reanastomosis.

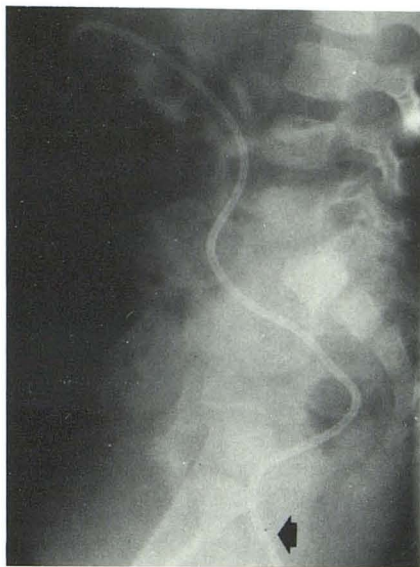

Fig. 4.—Case 4, 18-month-old boy with shunt tube perforating colon and protruding from rectum (arrow). Peritoneal end was revised and perforated bowel repaired without infection.

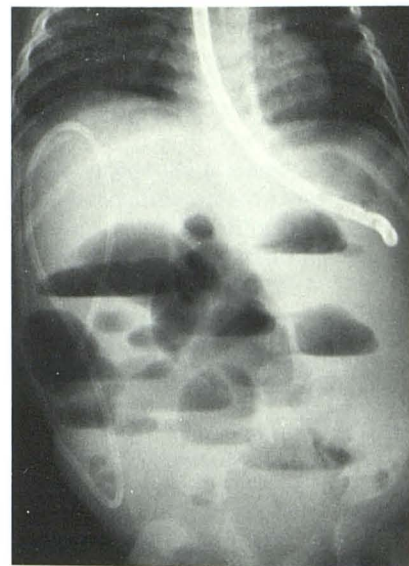
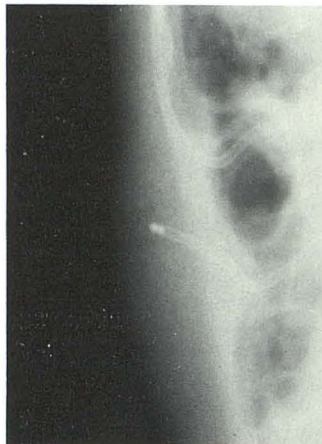

Fig. 5.—Case 5, 6-month-old girl with small bowel obstruction resulting from shunt tubing wrapped around loop of ileum.

Fig. 6.—Case 6. Shunt peritoneal tip embedded in umbilical hernia causes subcutaneous edema. Shunt functioned well after revision.



shunt became disconnected at the juncture of tubing with pumping system (fig. 3). The distal end migrated into the abdomen, and CT showed enlarged ventricles. The shunt was reconnected and worked well; his ventricles returning to normal size. Case 4 is an unusual case in which the peritoneal end of a ventriculoperitoneal shunt in an 18-month-old boy with intraventricular obstructive hydrocephalus migrated through the bowel wall and dangled from the rectum (fig. 4). CT and physical examination confirmed the shunt to be functioning well, but the distal limb had to be replaced in the peritoneal cavity. Surprisingly, the patient had no apparent infection. In addition to this case, three other instances of perforation of a viscus by a shunt tip were observed in our series, including the next case.

Case 5, a 16-month-old girl shunted for extra ventricular obstructive hydrocephalus, illustrates many of the problems with peritoneal shunts. She had a ventriculoatrial shunt initially which was revised once because of growth, then changed to a ventriculoperitoneal shunt after a shunt infection. The ventriculoperitoneal shunt was revised when she developed an acute abdomen. At laparotomy, the peritoneal end was implicated in a perforation of the gallbladder and two lacerations of the liver. Twice after this a small bowel obstruction was repaired with takedown of adhesions; on one of these occasions the shunt tubing was found to be knotted tightly around the bowel (fig. 5).

In case 6, a peritoneal end was noted to migrate into an umbilical hernia (fig. 6), causing cerebrospinal fluid subcutaneous edema. Distal ends have been known to cause peritoneal cerebrospinal fluid cysts in areas of loculated fibrosis or in cases where the greater omentum blocks the shunt tip; in our group the greater omentum was noted to have migrated to the peritoneal shunt tip and was obstructing it at laparotomy in three cases. Cerebrospinal fluid then backs up and hydrocephalus is exacerbated, requiring revision. Despite their frequency, ventriculoperitoneal shunt

Ventriculoperitoneal Shunts

Since they are more popular, ventriculoperitoneal shunts showed most of the complications in our series but had a complication rate of only 47%. This agrees with earlier findings that ventriculoperitoneal shunts had fewer and less serious complications than ventriculoatrial shunts [13–15]. About half (20/45 in our series) of all complications leading to surgical revision involved the distal (peritoneal) end. The other complications, 19 involving the ventricular end and six infections, were excluded as not being peculiar to the ventriculoperitoneal shunt system. Plain radiographs are most useful when the shunt tubing becomes shortened or disconnected, as observed in eight and four of our cases, respectively. Although all disconnections occurred in ventriculoperitoneal shunt patients in our series, they have also been seen in ventriculoatrial shunts, sometimes resulting in embolism of the separated end through the vascular system [11].

Case 3 is a 9-year-old child whose ventriculoperitoneal

complications are believed to cause less total mortality and morbidity than the intravascular complications of ventriculoatrial shunts [15–22].

Discussion

Hydrocephalus is caused by obstruction anywhere along the pathway from cerebrospinal fluid production to absorption [23, 24]. Intraventricular obstructive hydrocephalus will occur with obstruction anywhere from the lateral ventricle to the exit foramina of the fourth ventricle [24, 25]. Extraventricular obstructive hydrocephalus replaces the old term of communicating hydrocephalus and denotes obstruction to the reabsorption of cerebrospinal fluid flow by processes scarring or blocking the arachnoid granulations and the subarachnoid spaces.

The concept of shunting involves mechanical redirection of cerebrospinal fluid from an obstructed cavity to an area capable of fluid reabsorption. Just about any body cavity capable of reabsorbing fluid has been used by surgeons at one time as a repository for cerebrospinal fluid [24, 25]. Surgically, one end of a Silastic tube is placed into a lateral ventricle, usually the right, via a burr hole. A Holter, Pudenz, Portonoy, or Hakim valve will provide unidirectional flow of cerebrospinal fluid and is capable of transcutaneous flushing. The distal tubing is placed in a receptacle organ or cavity. If an obstruction is located intraventricularly, a shunt may be directed a short distance beneath the scalp into the cisterna magna to provide access to the normal subarachnoid reabsorptive sites. This simple bypass system, the Torkildsen procedure, is not used extensively today [26].

A popular shunting procedure in the 1950s was the ventriculoureteral shunt, in which the distal shunt was anastomosed with the free proximal end of a ureter after nephrectomy [27]. This operation has been abandoned, although the shunt had a good reputation for reliable function. Many patients with functioning ventriculoureteral shunts are still alive. The ventriculopleural shunt has been abandoned because of the often considerable resultant pleural effusion. Other abandoned sites of drainage have been to the cystic duct, Stensen's duct, thoracic duct, or fallopian tubes [26, 28]. If hydrocephalus is of the extraventricular obstructive variety, a shunting system from the lumbar subarachnoid space, subcutaneously directed around the flank and then inserted into the peritoneal cavity, can be useful. Scoliosis sometimes resulted in the growing child, whether due to previous hemilaminectomy [29] or to underlying disease such as neurofibromatosis, and its use is limited at this time. Other severe complications associated with these shunts include arachnoiditis and electrolyte imbalances.

REFERENCES

1. Murtagh FR, Quencer RM, Poole CA. Cerebrospinal fluid shunt function and hydrocephalus in the pediatric age group: a radiographic/clinical correlation. *Radiology* 1979;132:385–388
2. Fitz CR, Harwood-Nash DC. Computed tomography in hydrocephalus, CT. *J Comput Assist Tomogr* 1978;2:91–107
3. Kingley D, Kendall BE. The value of CT in the evaluation of enlarged head. *Neurology (Minneapolis)* 1978;15:59–71
4. Larson EV, Omenn GS, Mango J. Impact of CT on the care of patients with suspected hydrocephalus. *AJR* 1978;131:41–44
5. Naidich TP, Epstein F, Lin JP, Kricheff II, Hochwald GM. Evaluation of pediatric hydrocephalus by CT. *Radiology* 1978;119:337–347
6. Epstein F, Naidich T, Kricheff II, Chase N, Lin JP, Ransohoff J. Role of CT in diagnosis, treatment and followup of hydrocephalus. *Childs Brain* 1977;3:91–100
7. Altman J, James AE. Ventriculovenous cerebrospinal fluid shunts: x-ray analysis. *AJR* 1971;112:237–249
8. Kurlander GJ, Chua GT. Roentgenology of ventriculoatrial shunts for the treatment of hydrocephalus. *AJR* 1967;101:157–167
9. Cowan MA, Allen MD. Retrograde migration of venous catheter as a complication of ventriculoatrial shunt in adults. *J Neurosurg* 1971;35:348–350
10. Nugent GR, Lucas R, Judy M, Bloor BM, Wardern H. Thromboembolic complications of ventriculoatrial shunts. *J Neurosurg* 1966;24:35–52
11. McCulloch GAJ, Cartledge JMCP. Retrieval of detached shunt catheter from the heart. *J Neurosurg* 1975;42:98–100
12. Forest DM, Cooper GW. Complications of VA shunts: a review of 455 cases. *J Neurosurg* 1968;29:506–612
13. Little JR, Rhoton AL, Mellinger JF. Comparison of ventriculoperitoneal and ventriculoatrial shunts for hydrocephalus. *Mayo Clin Proc* 1972;47:396–401
14. Murtagh FR, Lehman R. Peritoneal shunts in the management of hydrocephalus. *JAMA* 1967;202:1010
15. Davidson RI. Peritoneal bypass in the treatment of hydrocephalus: historical review and abdominal complications. *J Neurol Neurosurg Psychiatr* 1976;39:640–646
16. Grosfeld JL, Cooney DR, Smith J, Campbell RL. Intraabdominal complications following ventriculoperitoneal shunt procedures. *Pediatrics* 1974;54:791–796
17. Ignelzi RJ, Kirsch WM. Analysis of ventriculoperitoneal and ventriculoatrial shunts for hydrocephalus. *J Neurosurg* 1975;42:679–682
18. Goldfine SC, Turetz F, Beck AR, Eiger M. Cerebrospinal fluid intraperitoneal cyst: an unusual abdominal mass. *AJR* 1978;130:568–569
19. Pierce KR, Loeser JD. Perforation of intestine by a Raimondi peritoneal catheter. *J Neurosurg* 1975;43:112–113
20. Parry SW, Schuhmacher JF, Llewellyn RC. Abdominal pseudocysts and ascites formation after ventriculoperitoneal shunt procedures. *J Neurosurg* 1975;43:476–483
21. Keen PE, Weitzner S. Inflammatory pseudotumor of mesentery: a complication of ventriculoperitoneal shunt. *J Neurosurg* 1973;38:371–372
22. Antunes ACM, Ribeiro TR. Spontaneous umbilical fistula from ventriculoperitoneal shunt drainage. *J Neurosurg* 1975;43:481–483
23. Milhorat TH. The third circulation revisited. *J Neurosurg* 1975;46:628–645
24. Harwood-Nash DC, Fitz CR. Hydrocephalus. In: *Neuroradiology in infants and children*. St. Louis: Mosby, 1976:609–667
25. Naidich TP, Gado M. Hydrocephalus. In: Newton TA, Potts DG, eds. *Radiology of the skull and brain*, vol 4, *Ventricles and cisterns*. St. Louis: Mosby, 1978:3764–3834
26. Matson DD. *Neurosurgery of infancy and childhood*, 2d ed. Springfield, IL: Thomas, 1968:98–106
27. Nashold BS, Mannarino E. Treatment of hydrocephalus by ureteral-subarachnoid shunt. *J Neurosurg* 1962;18:270–272
28. Holloway RM, Carter C. Hydrocephalus: a new surgical approach. *Arch Otolaryngol* 1971;93:568–575
29. Murtagh FR, Lehman R. Use of lumboperitoneal shunt in hydrocephalus. *JAMA* 1967;202:543–555